

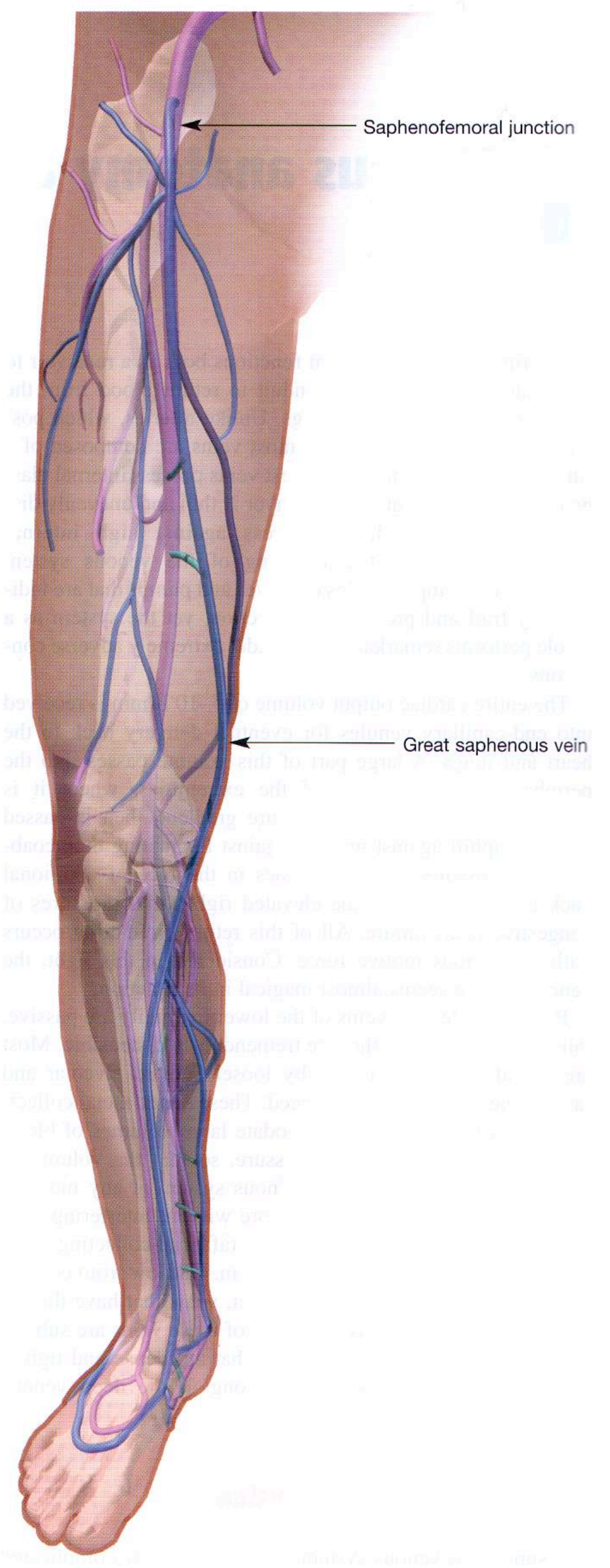
# Anatomía Venosa y Linfática Enfoque funcional

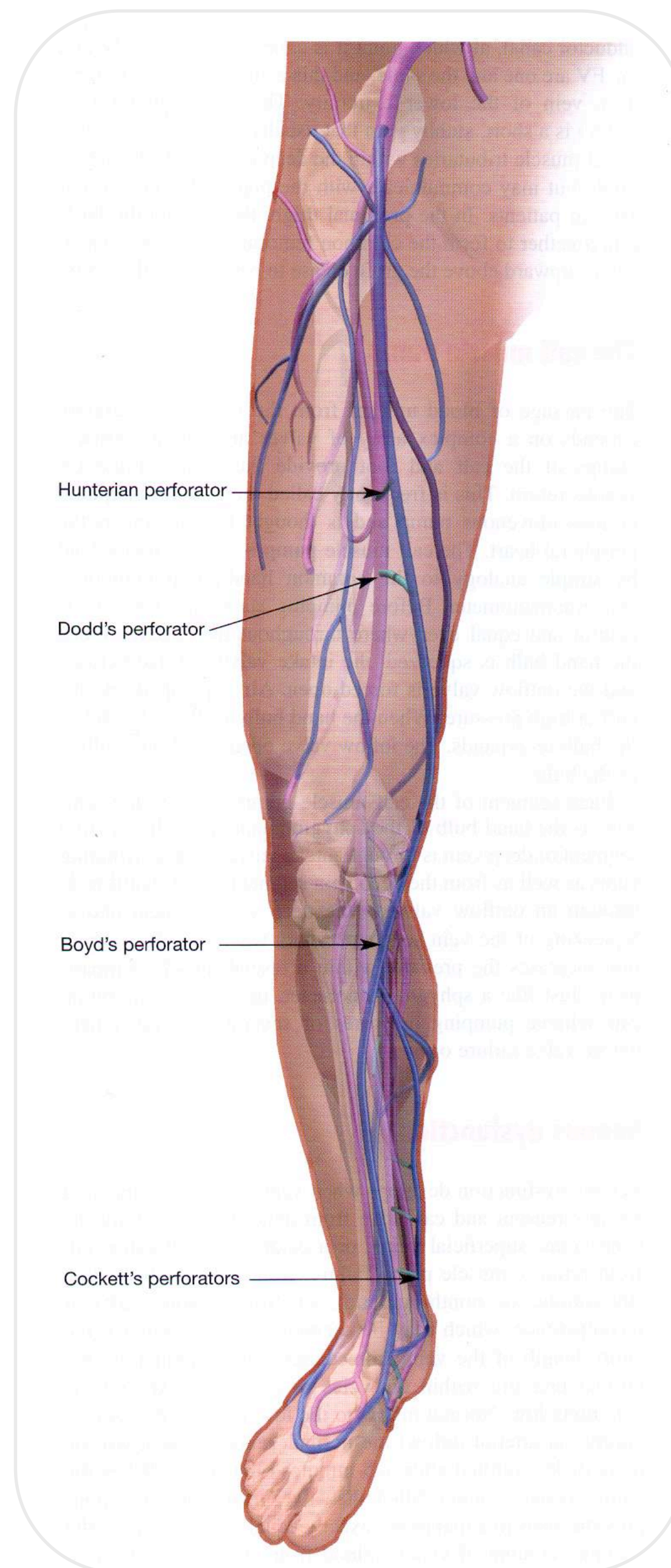
Dr. Alejandro Cabrera M.


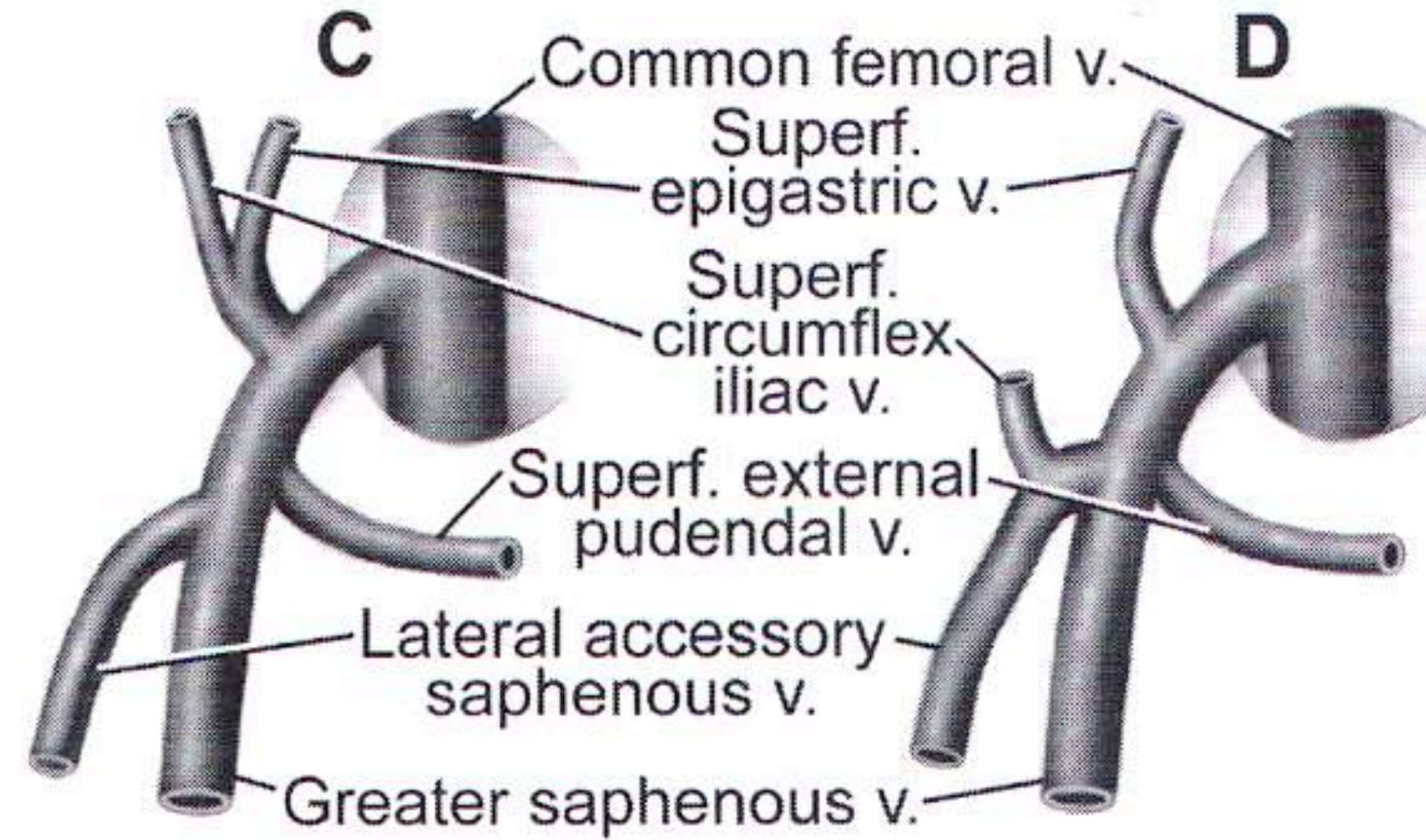
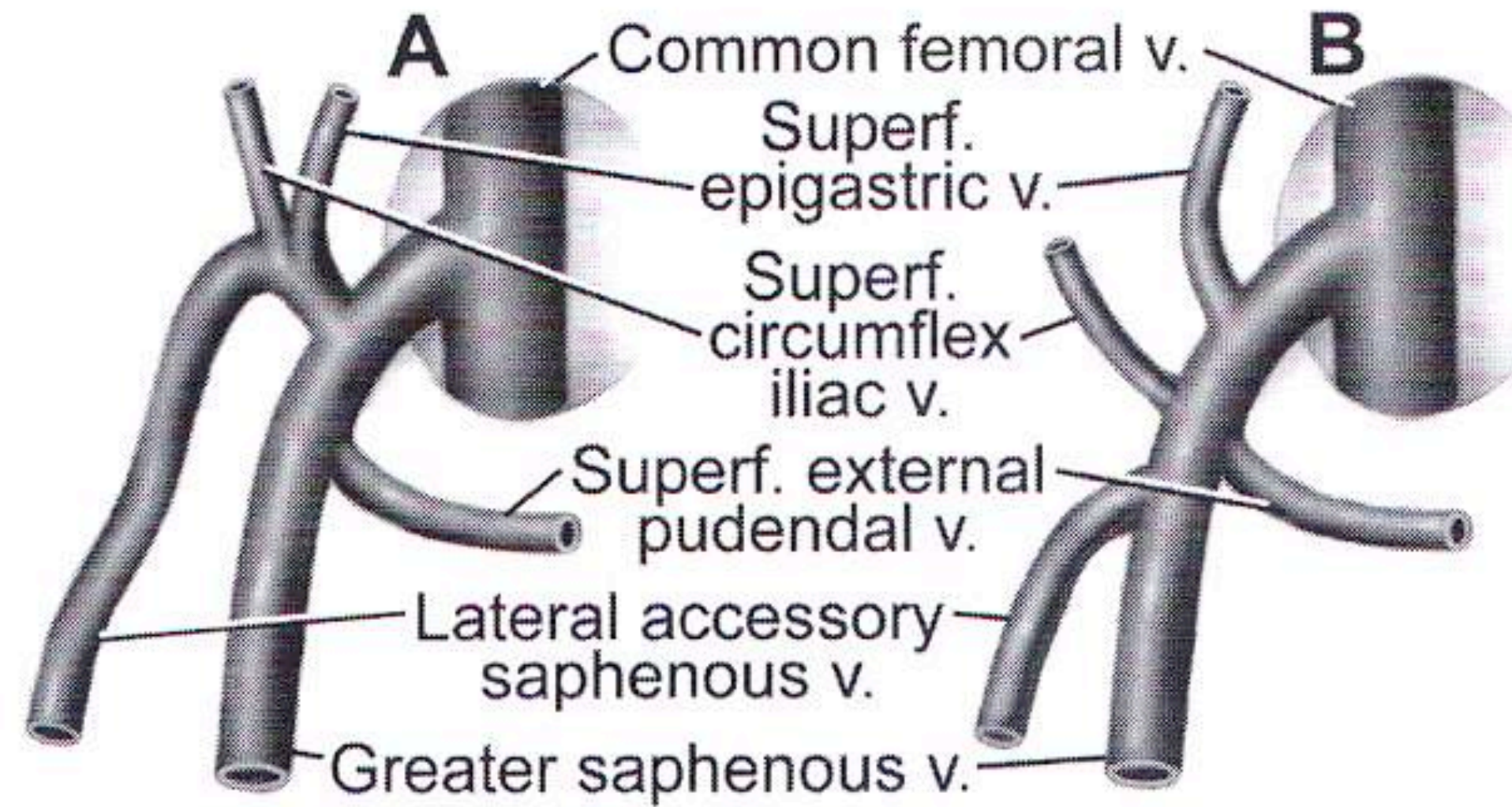
# Sistema venoso superficial

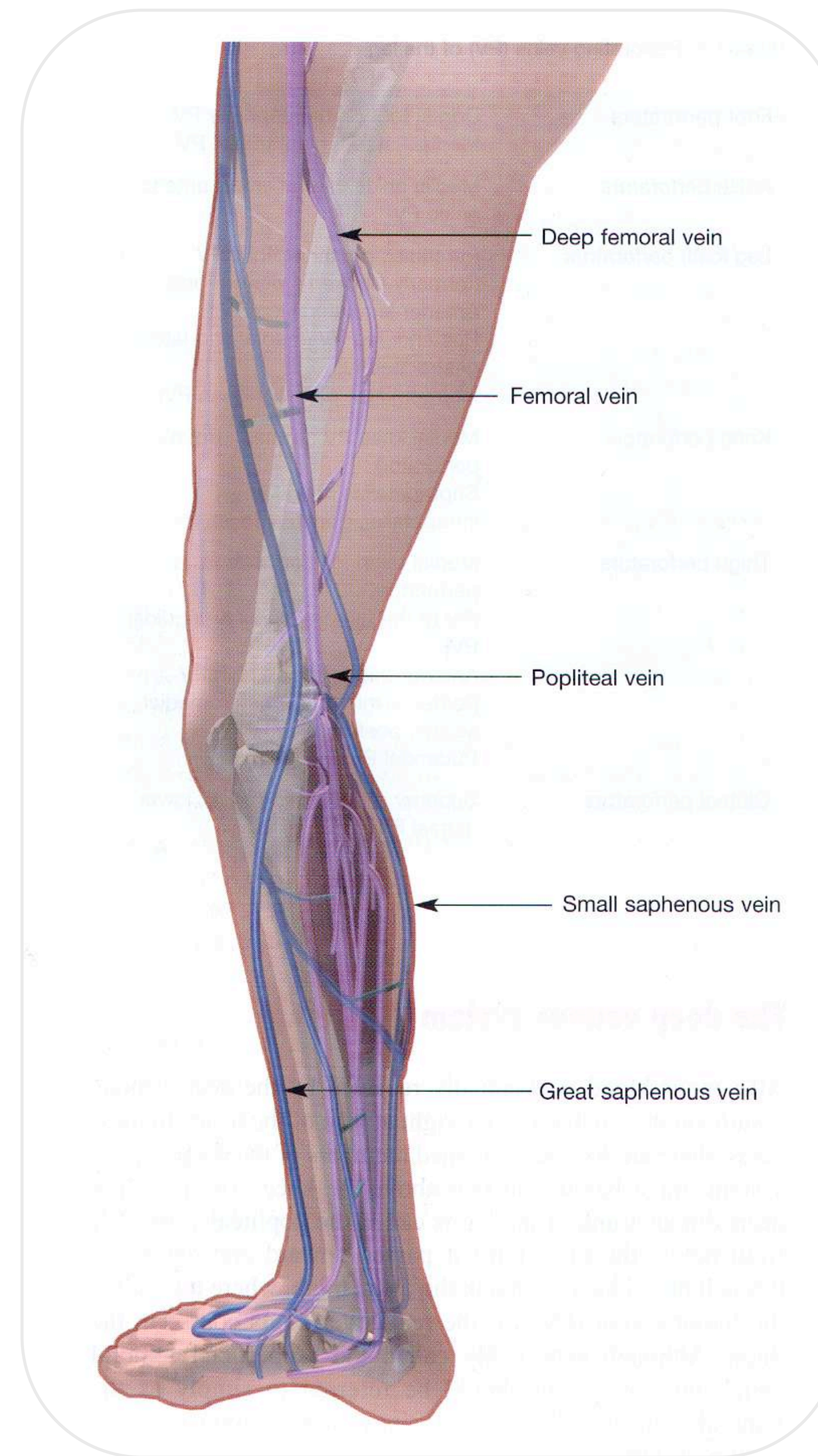
# Sistema venoso profundo

# Disfunción Venosa

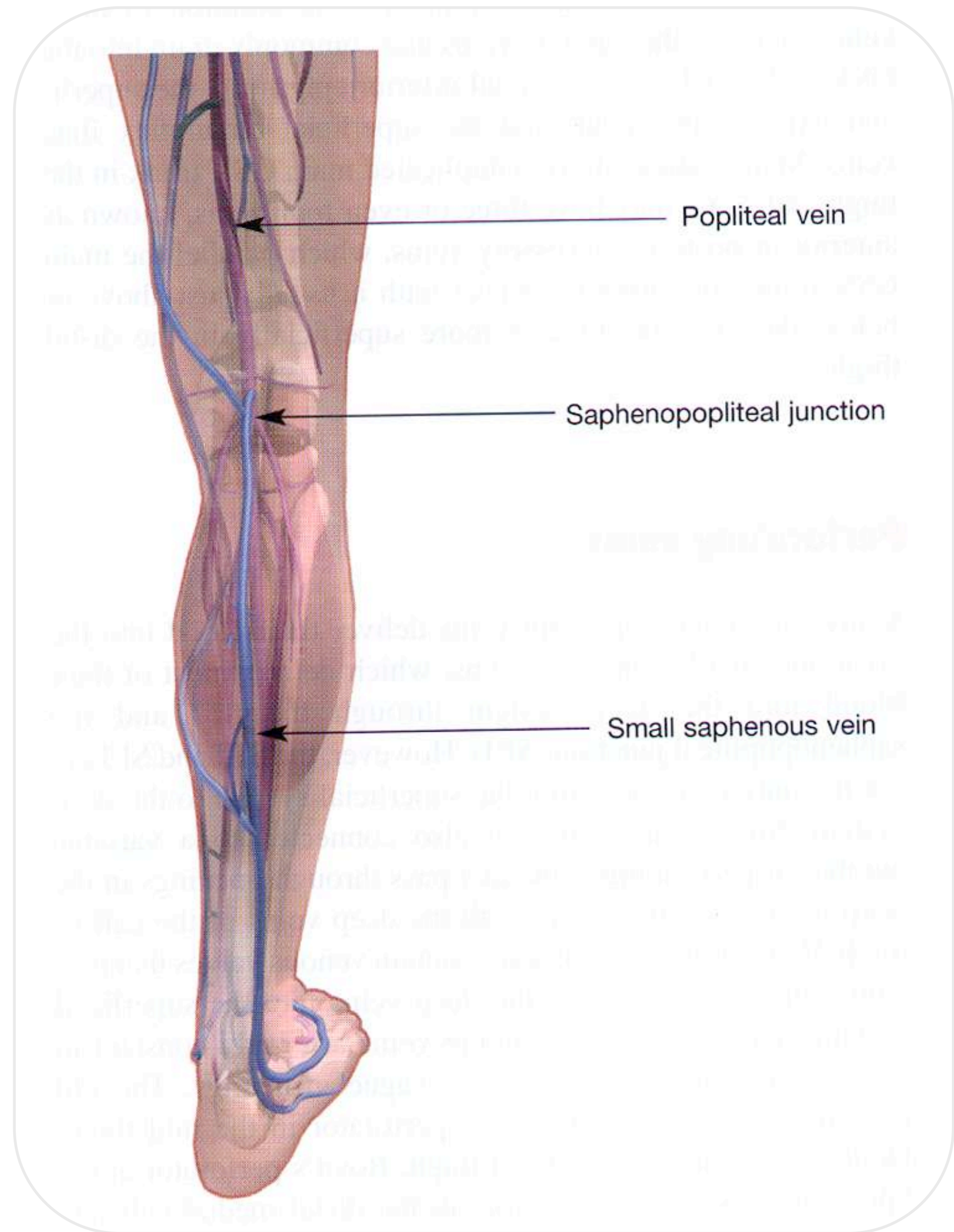


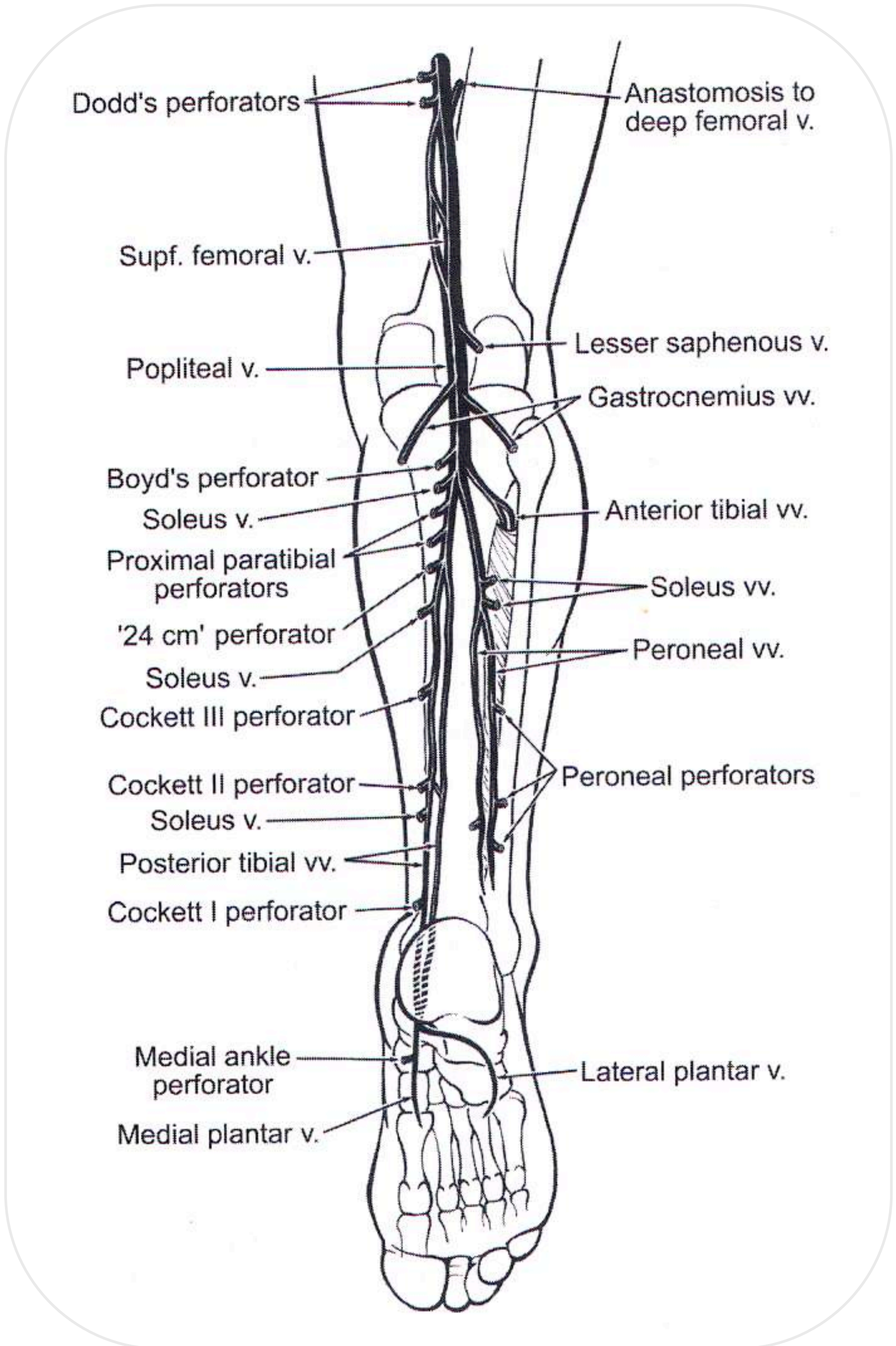


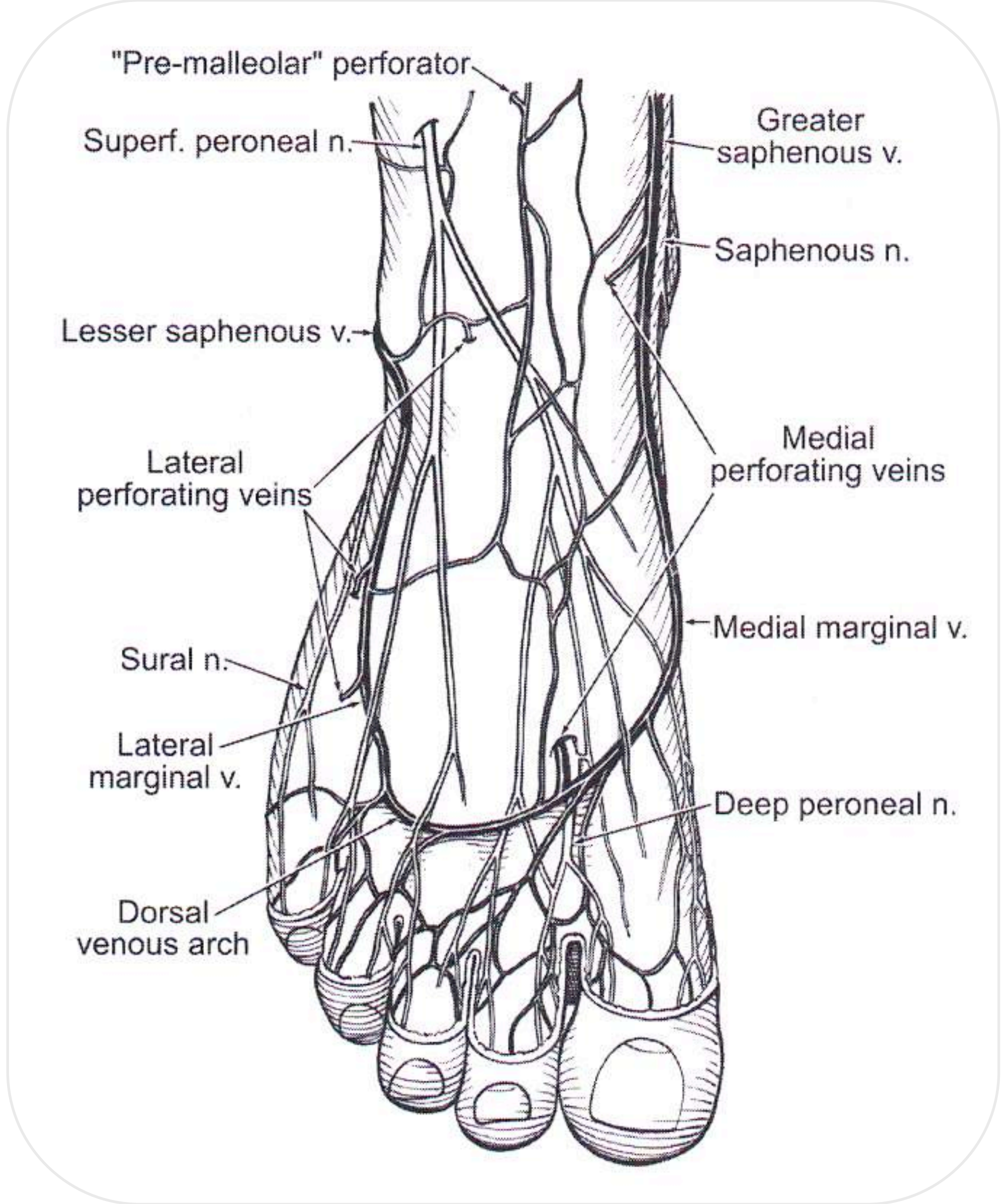




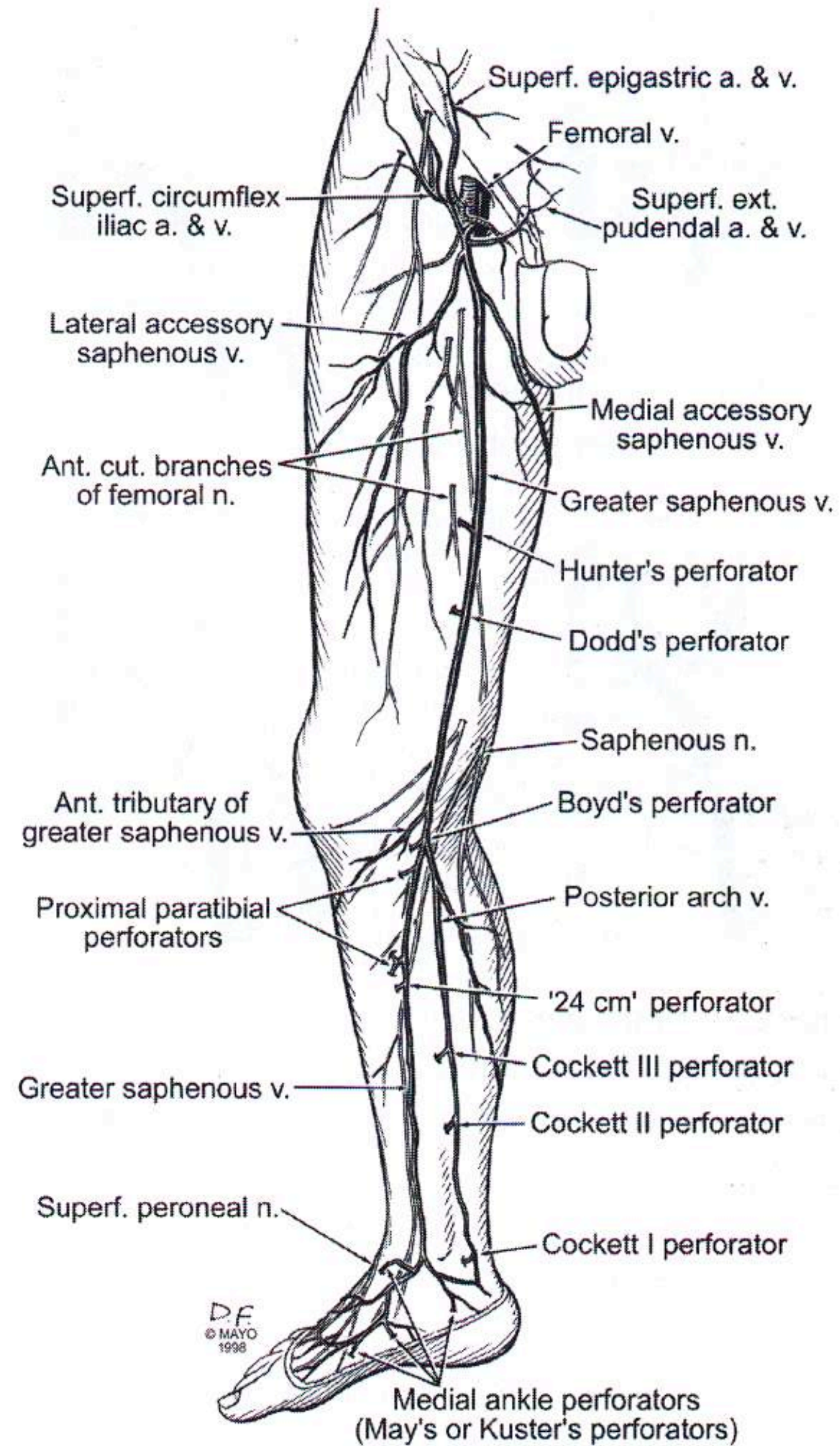


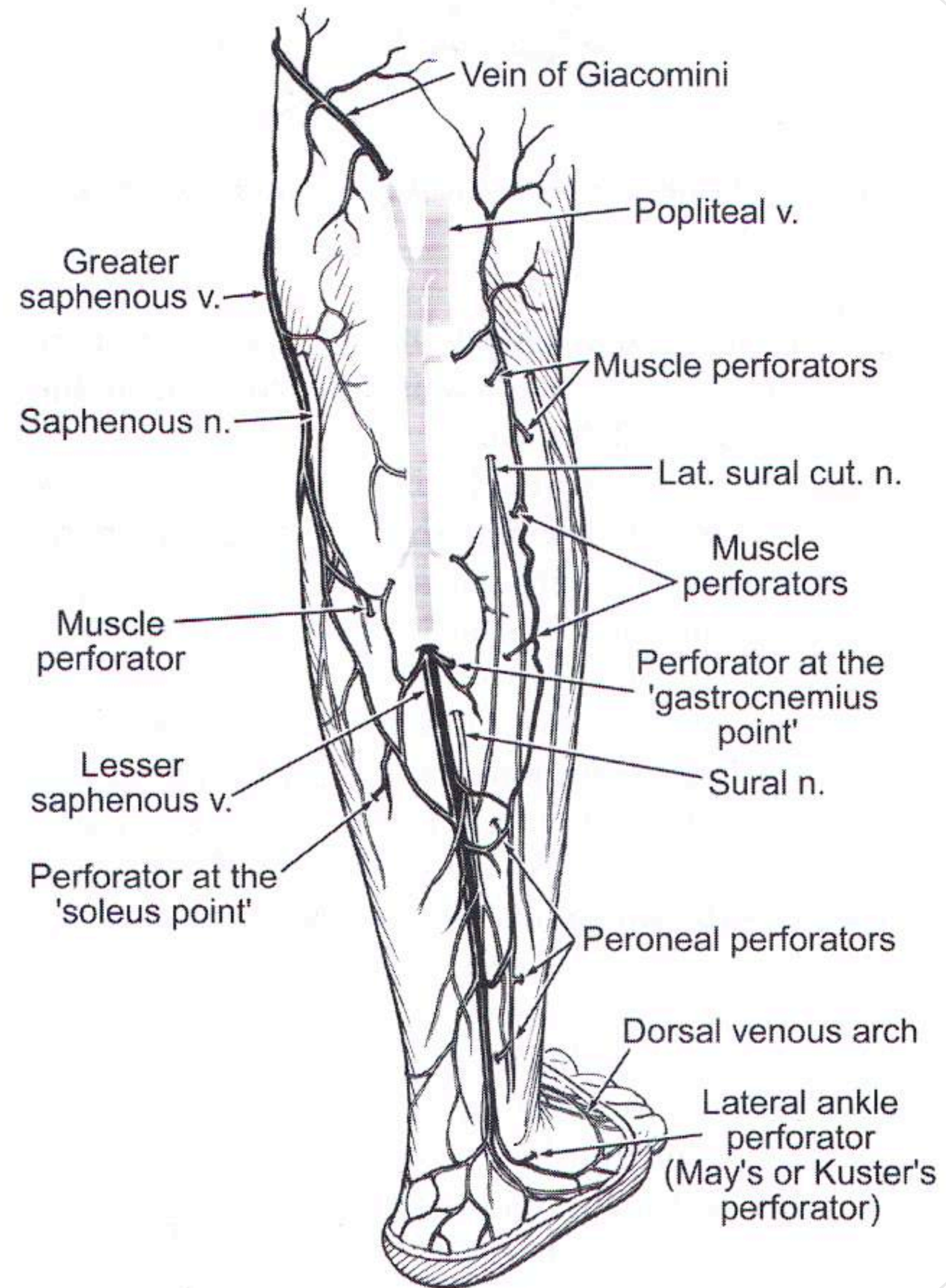


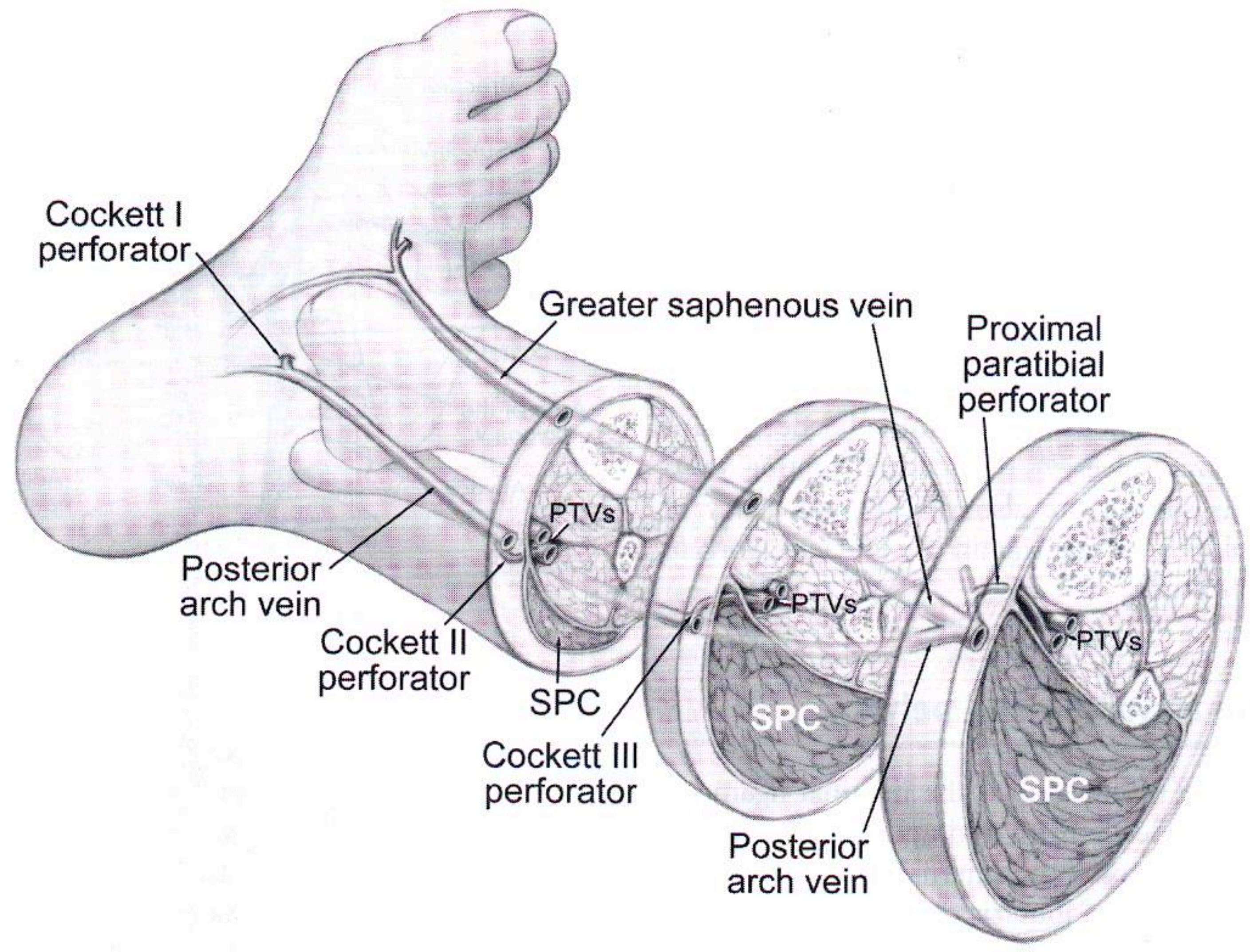


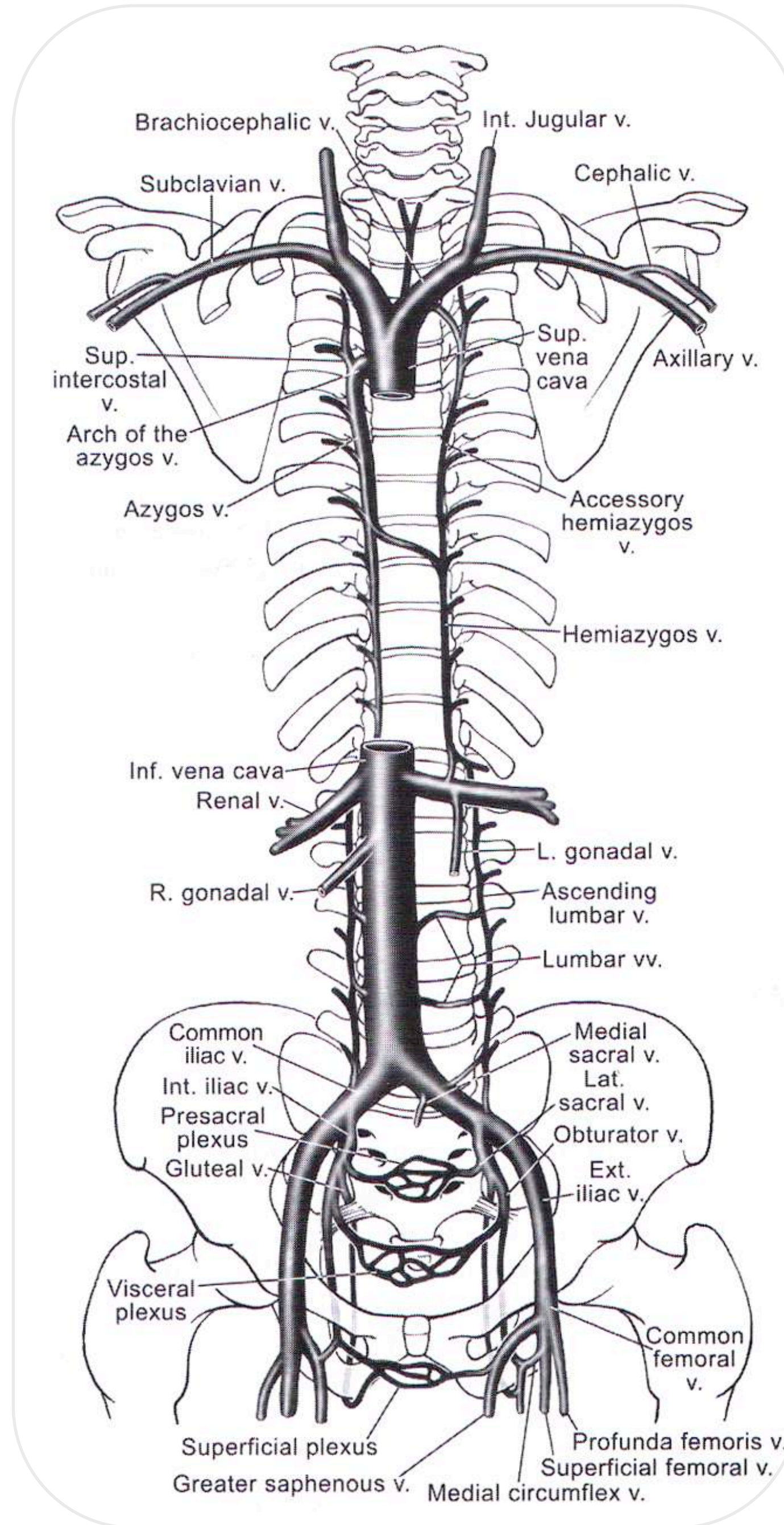


# Venas perforantes

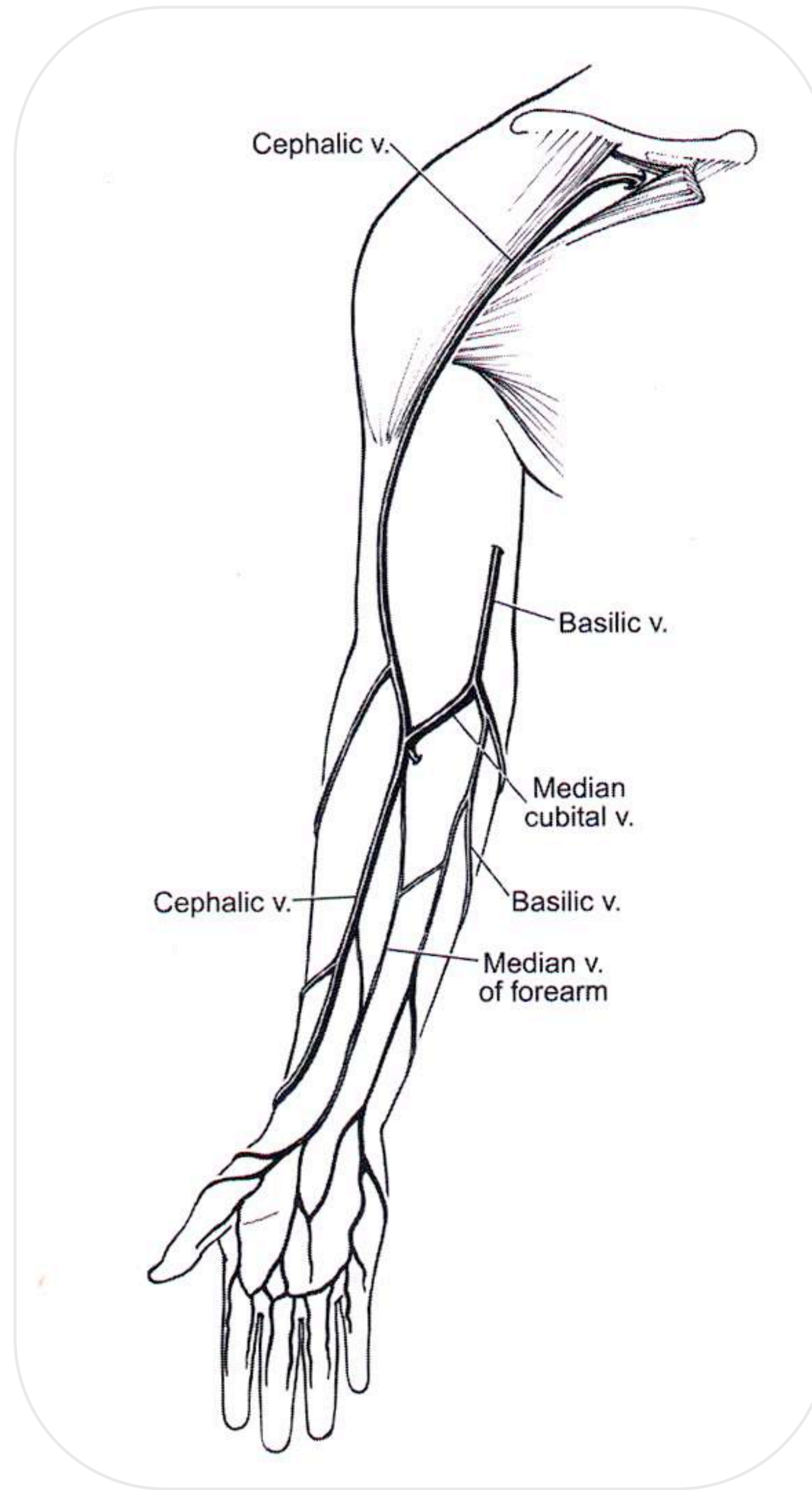


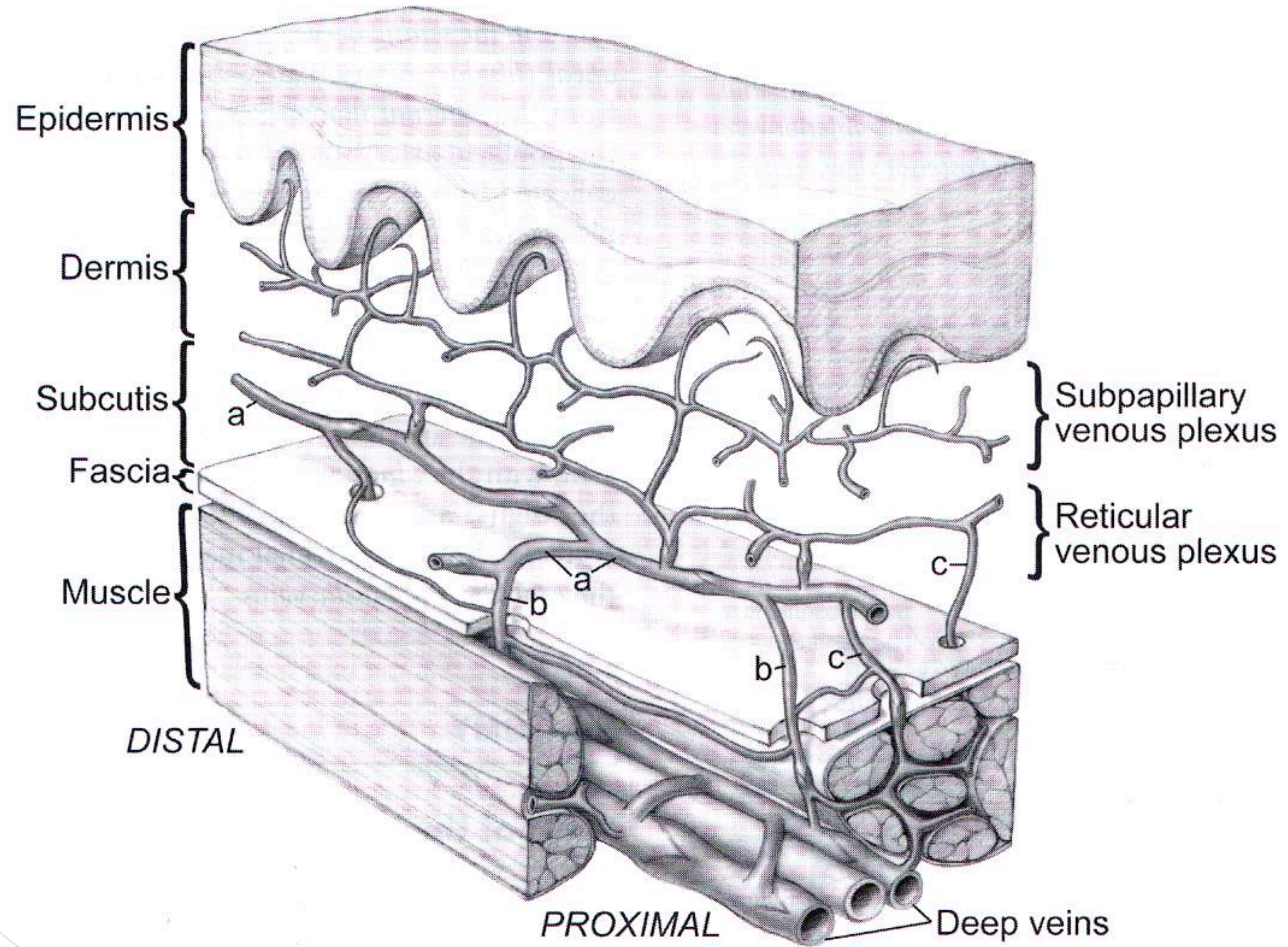




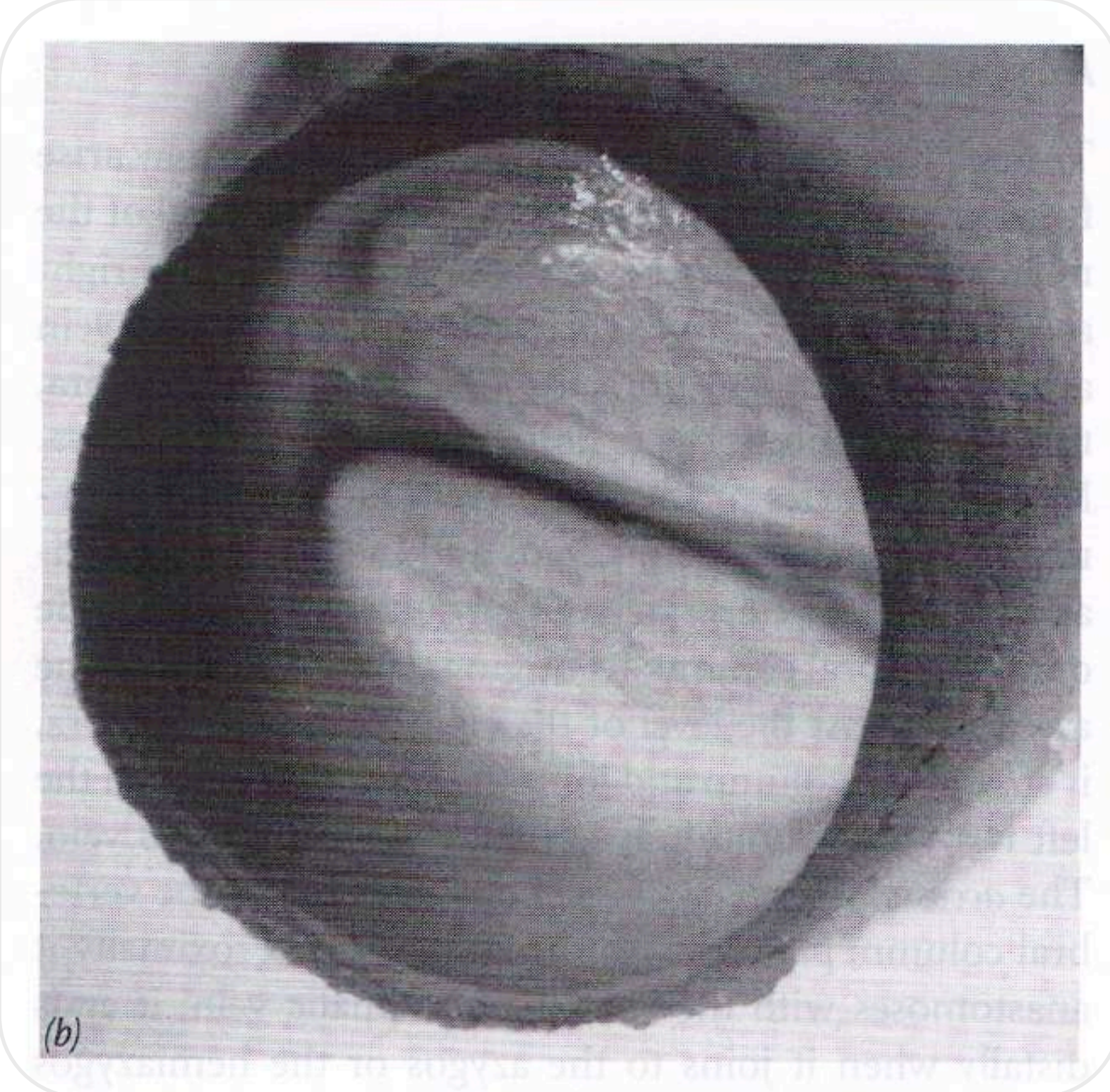
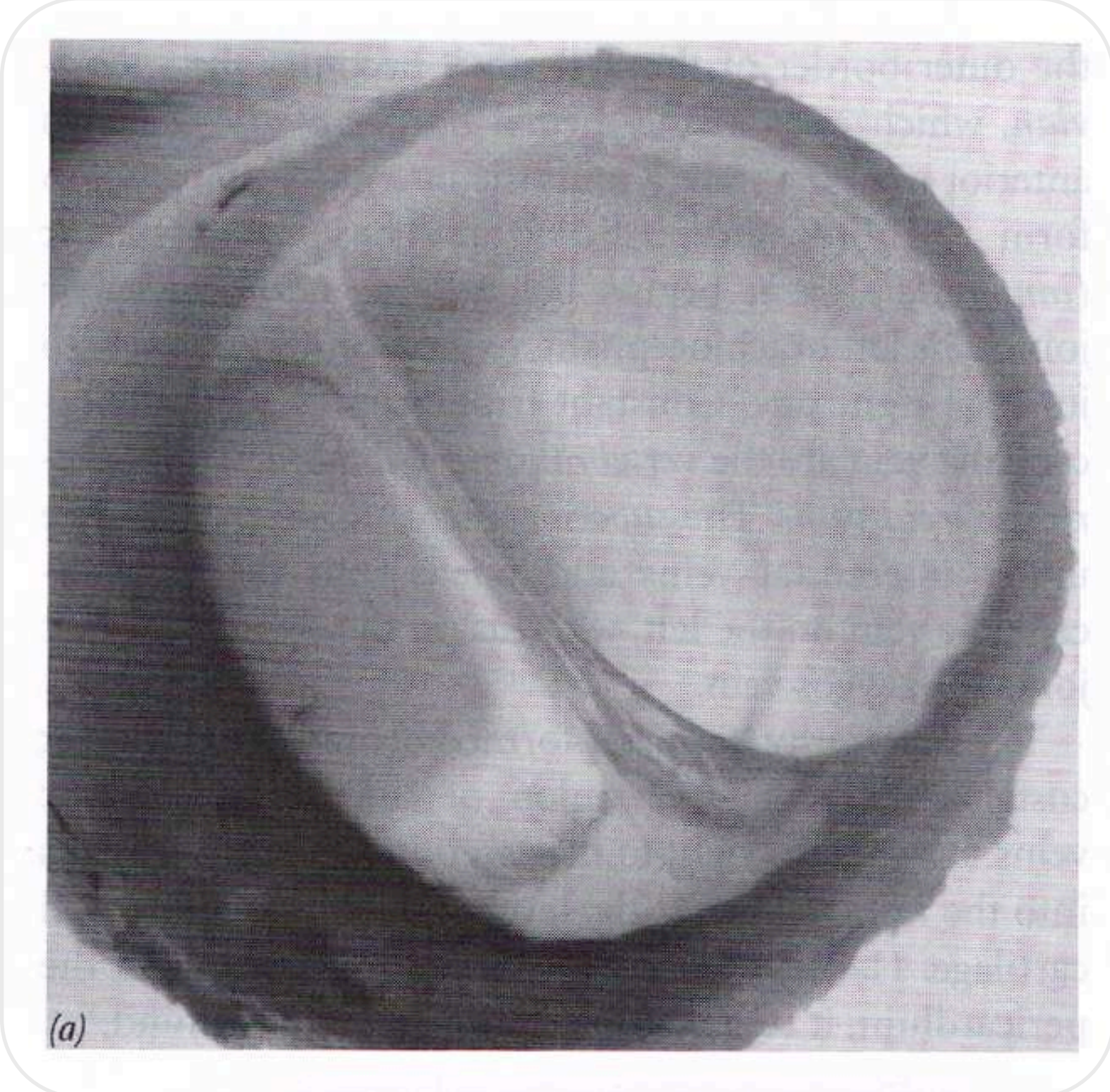


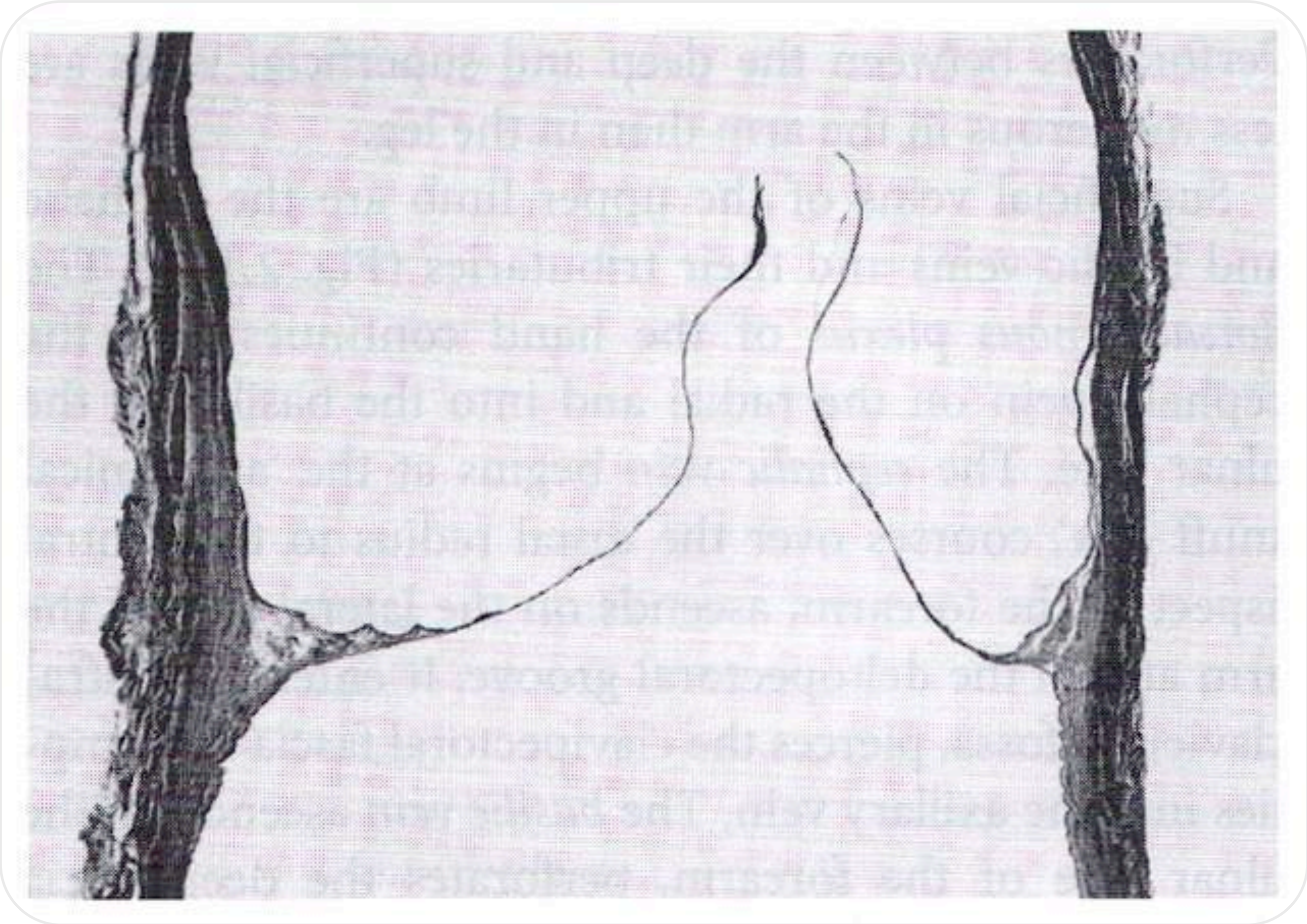


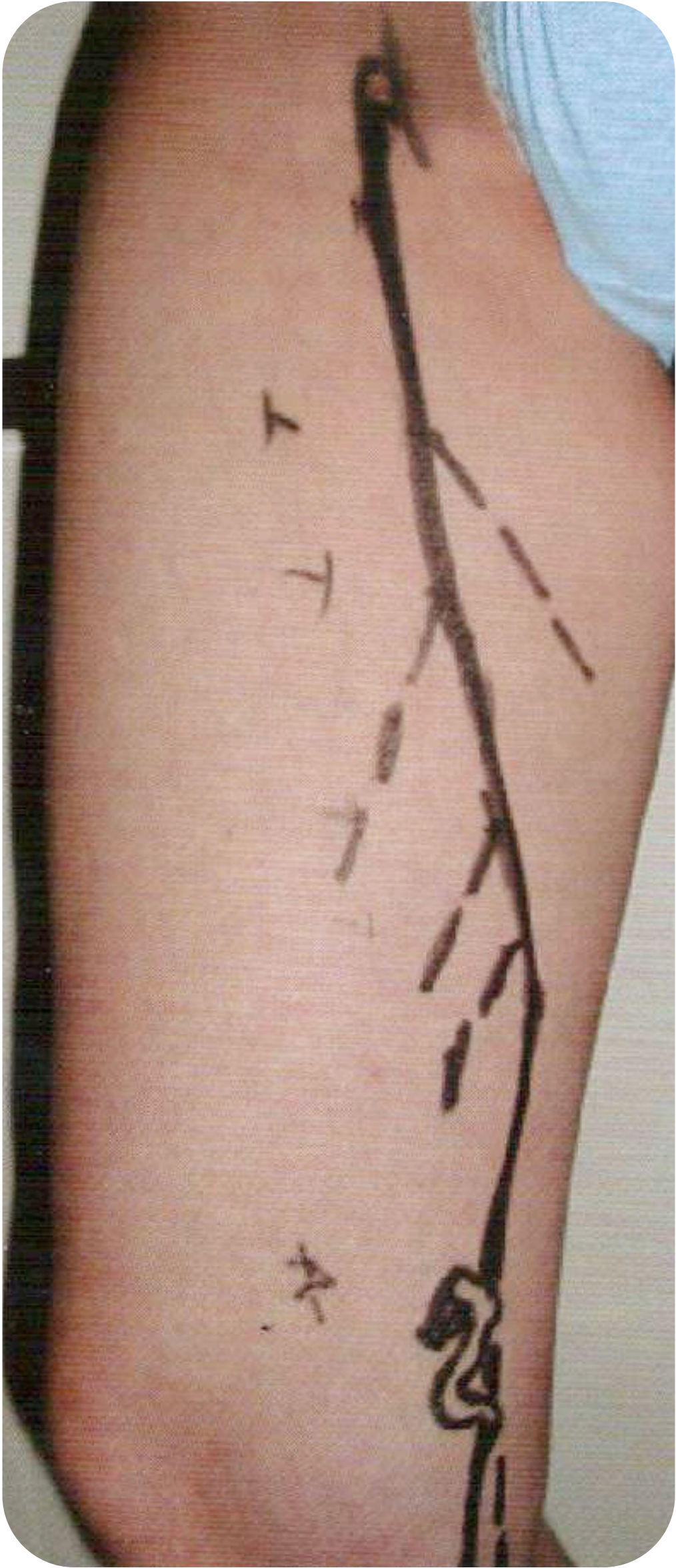


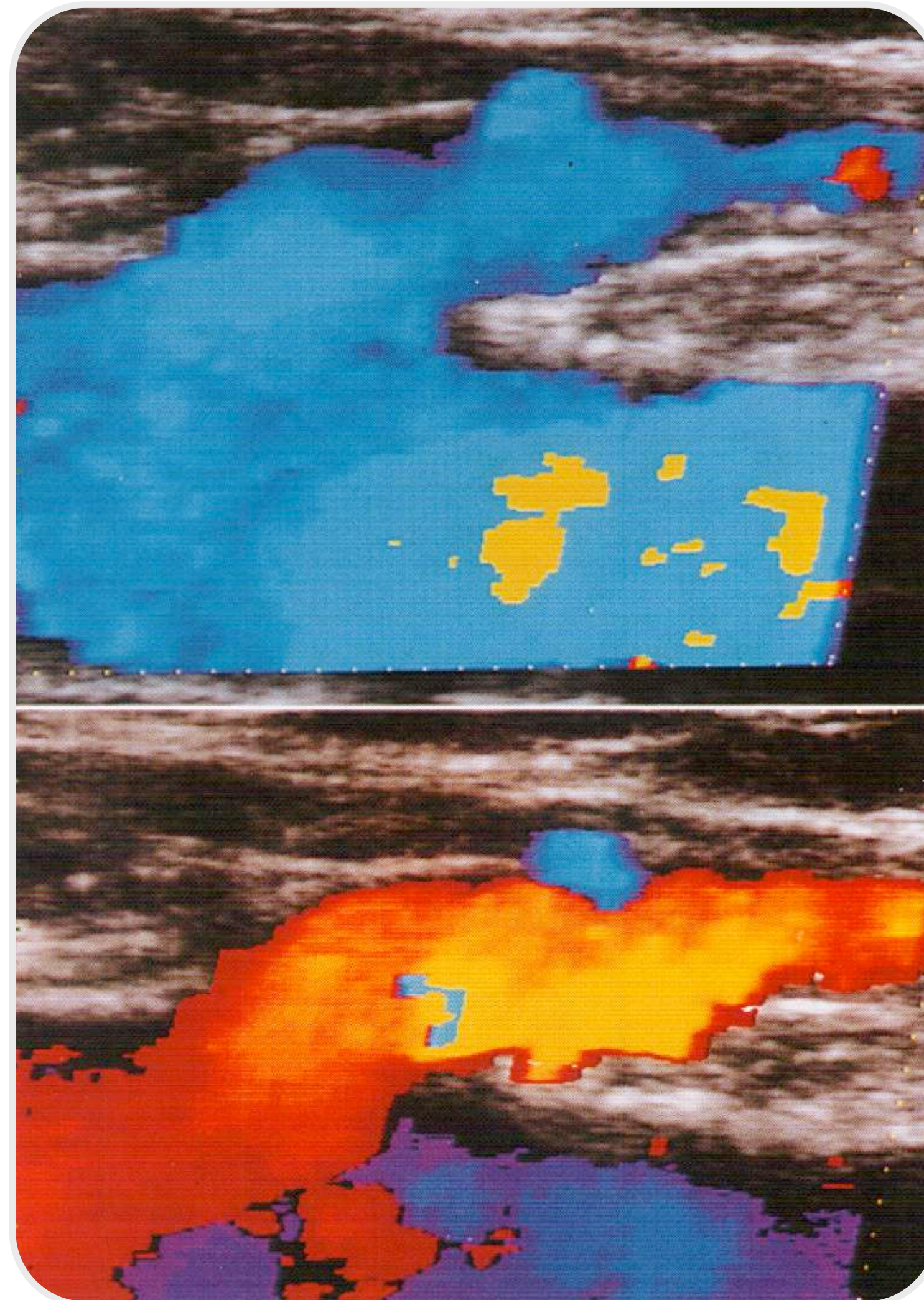


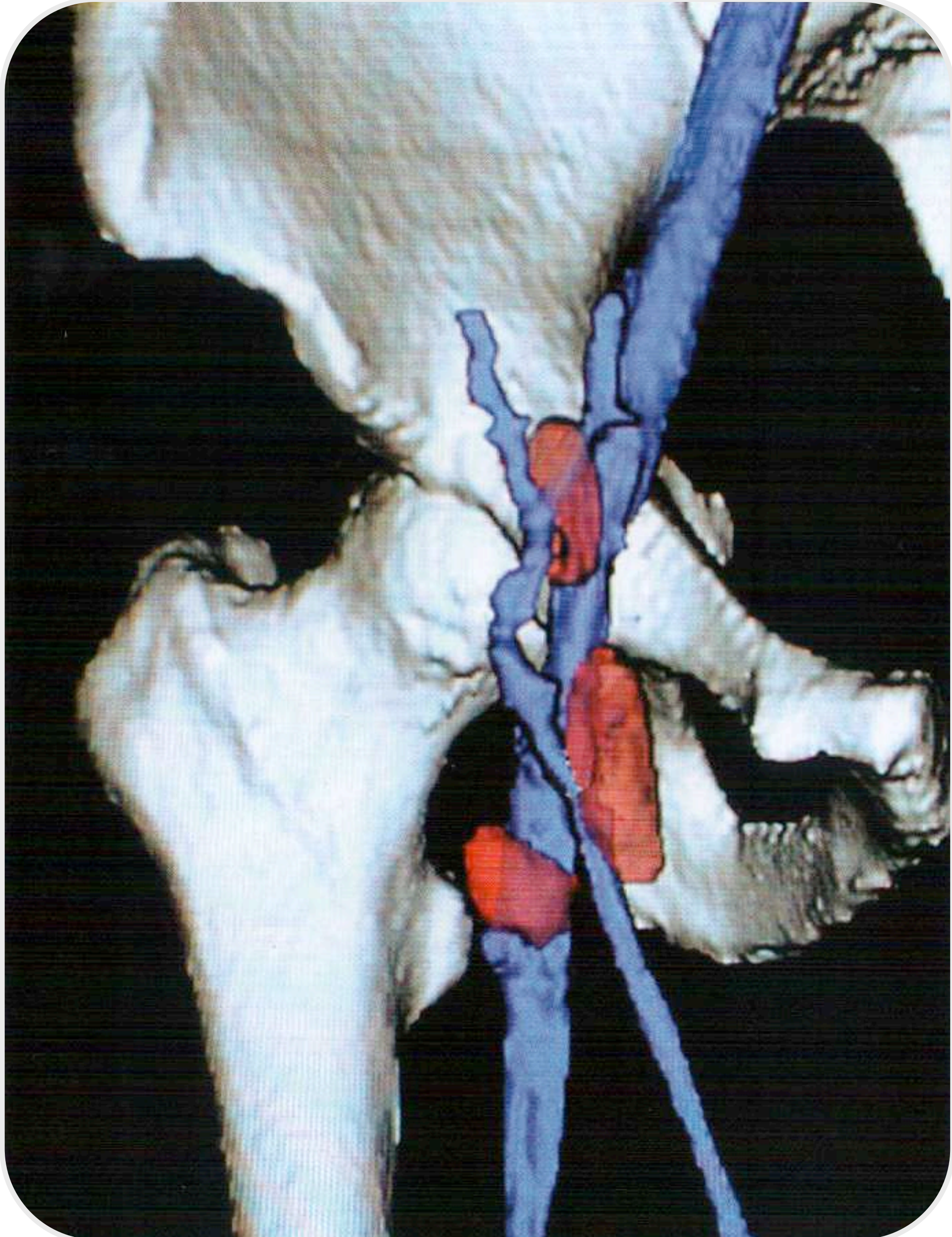
PROXIMAL Deep veins

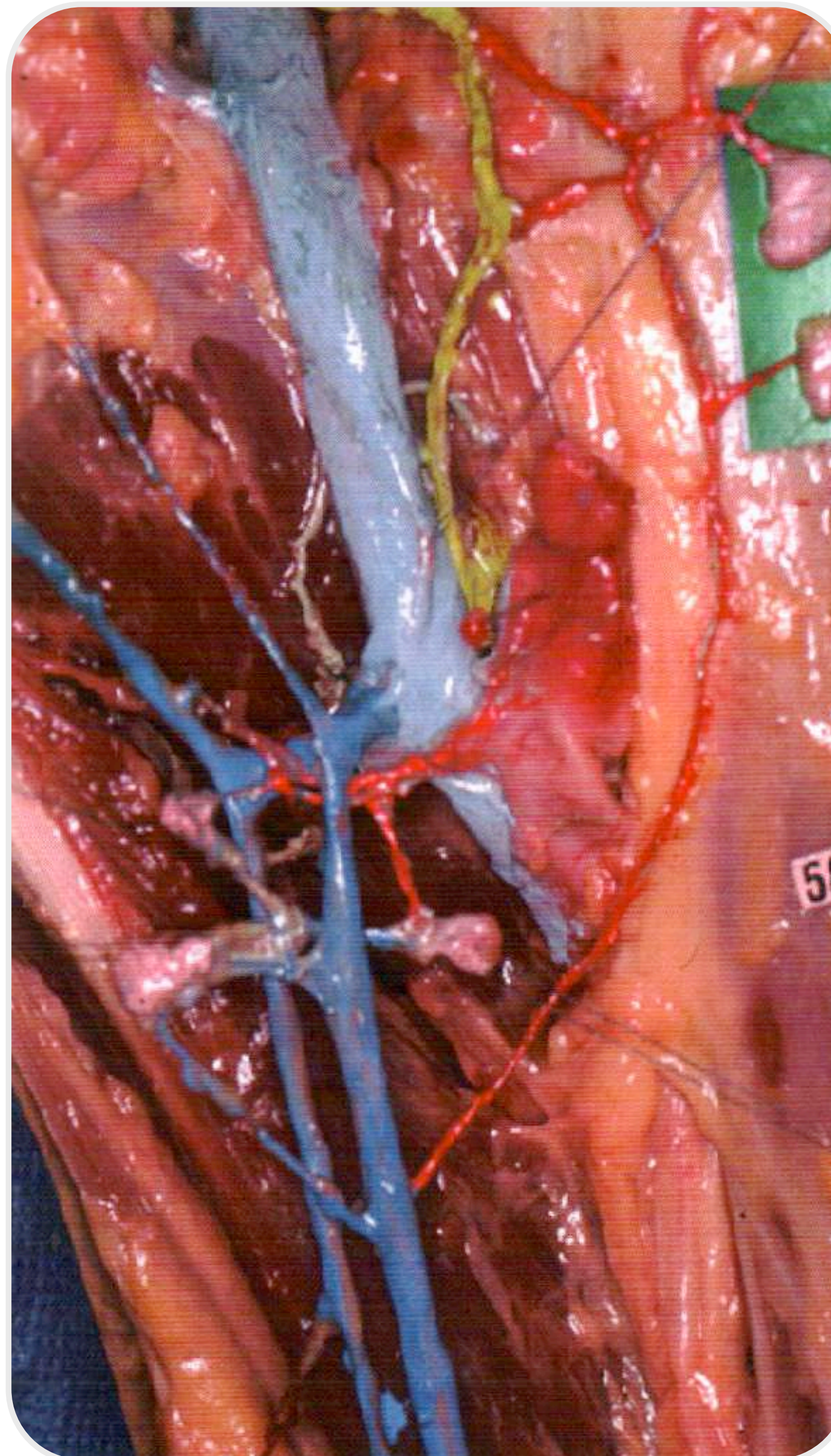




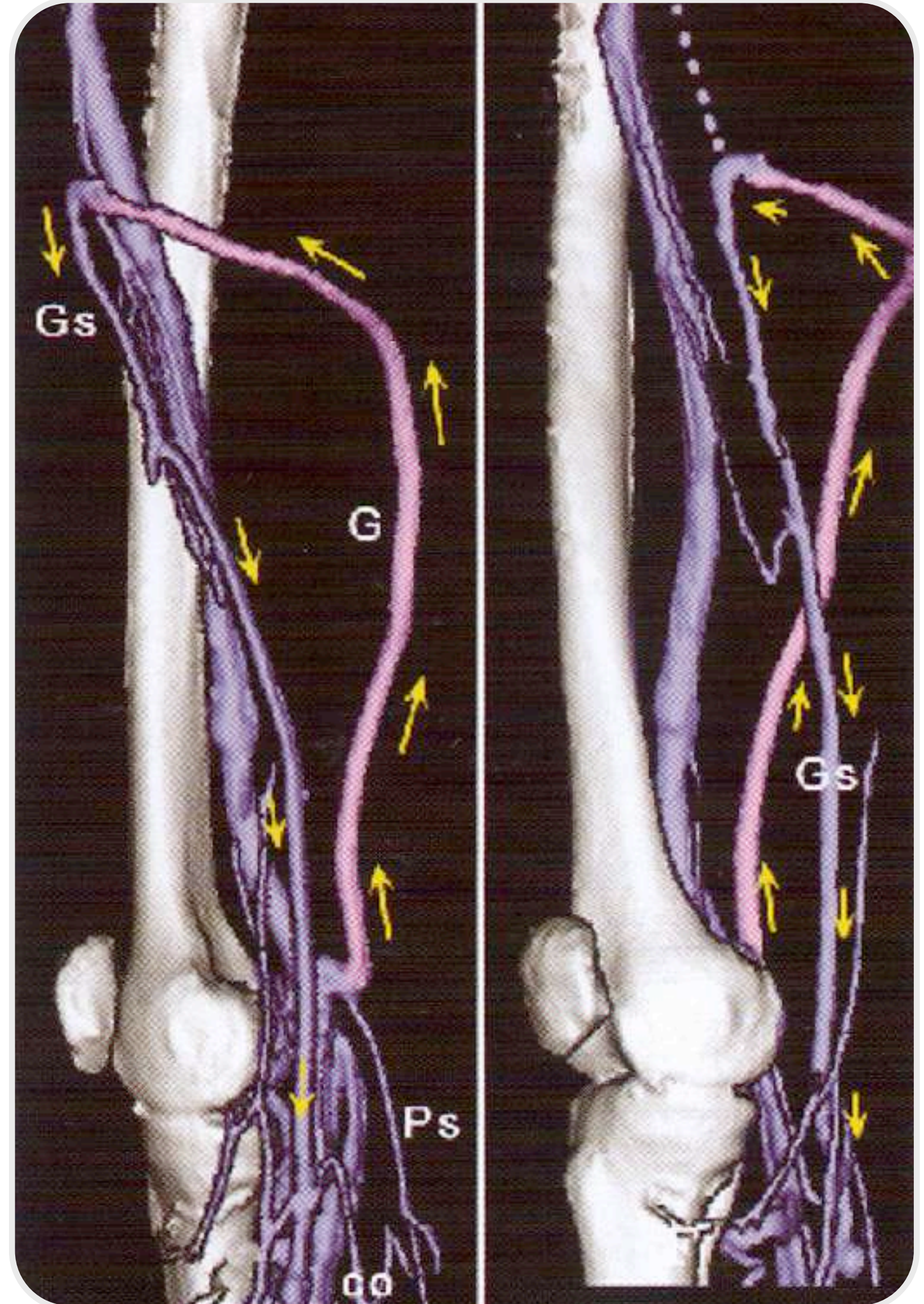
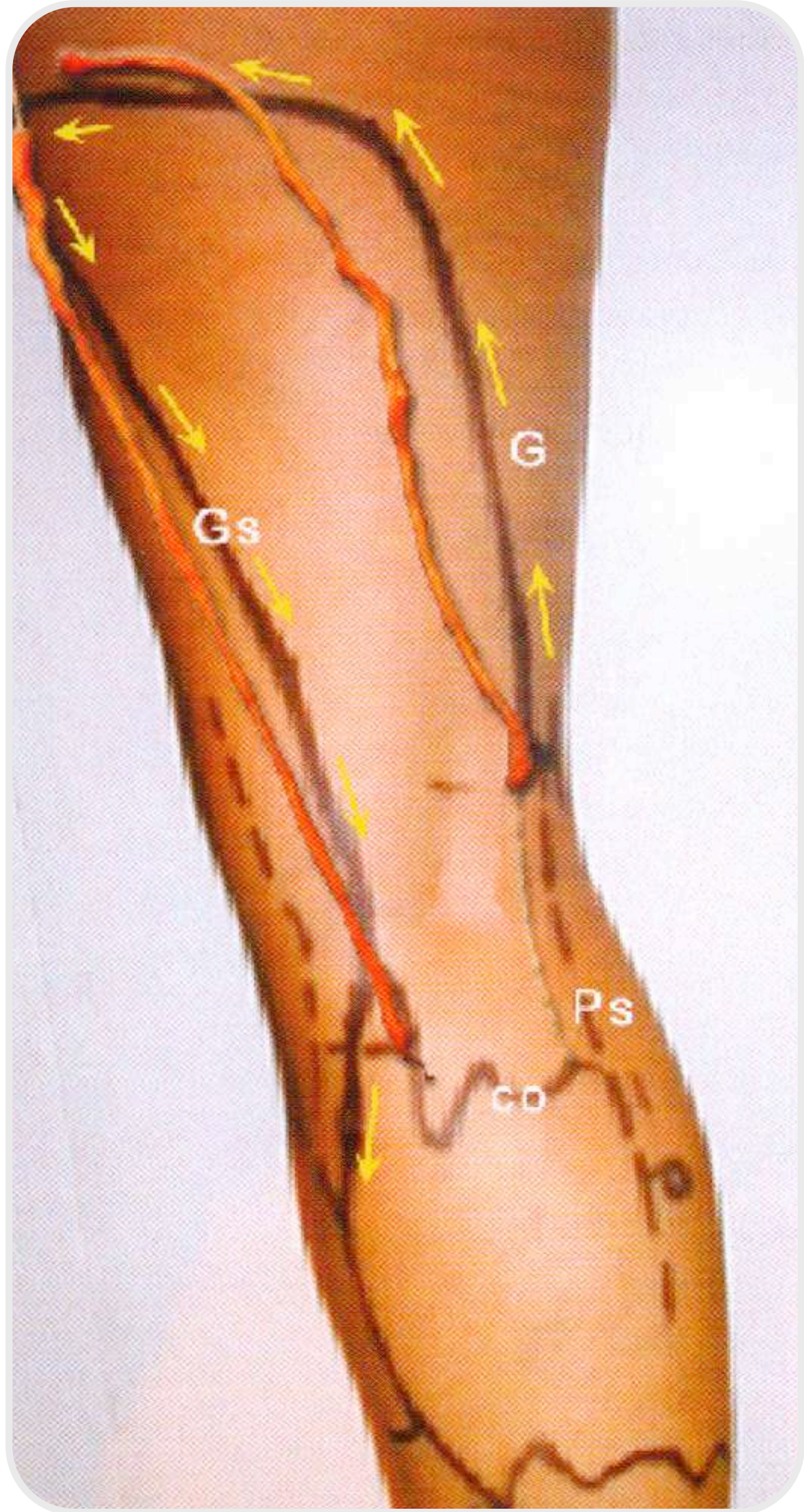


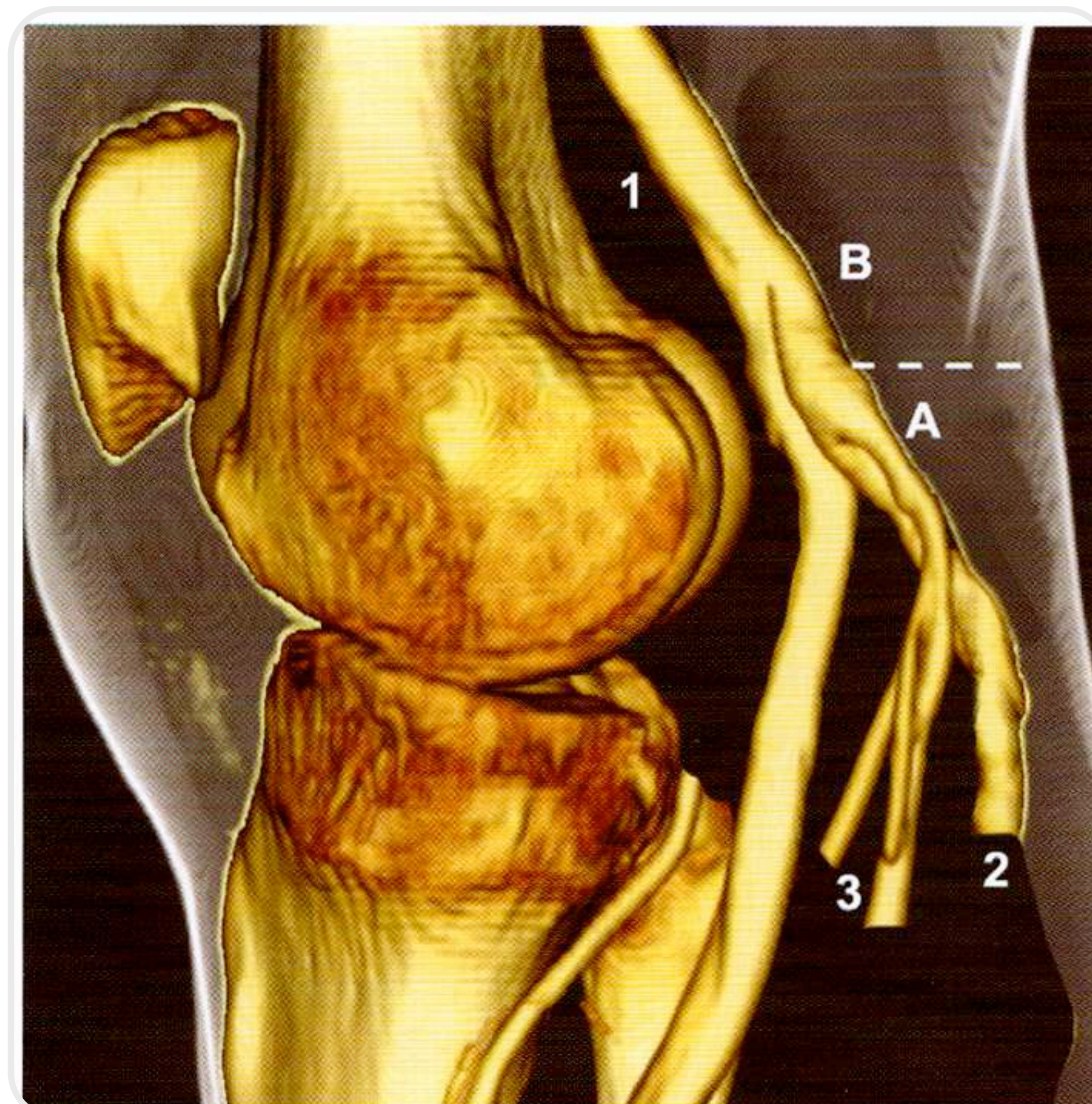


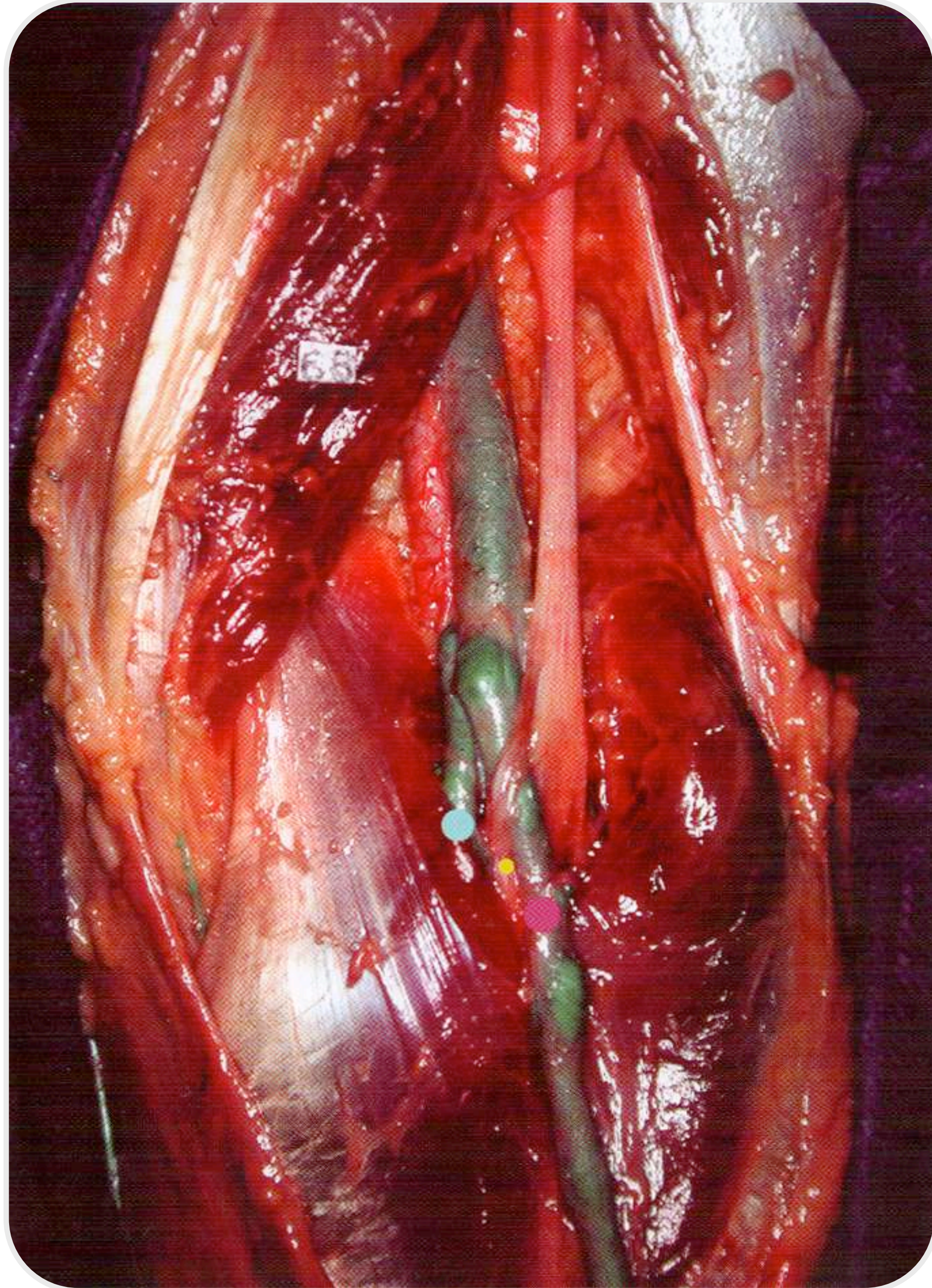


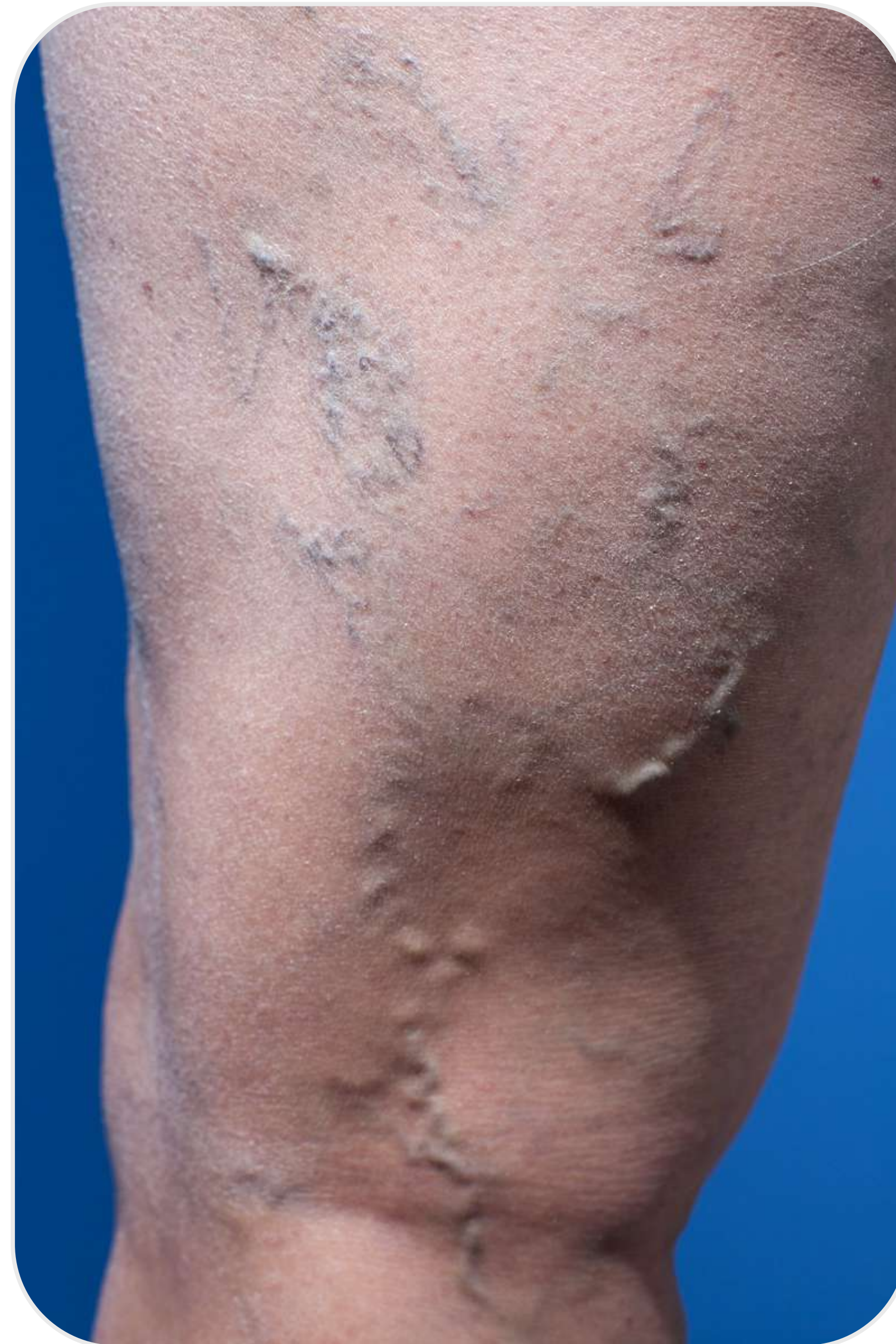


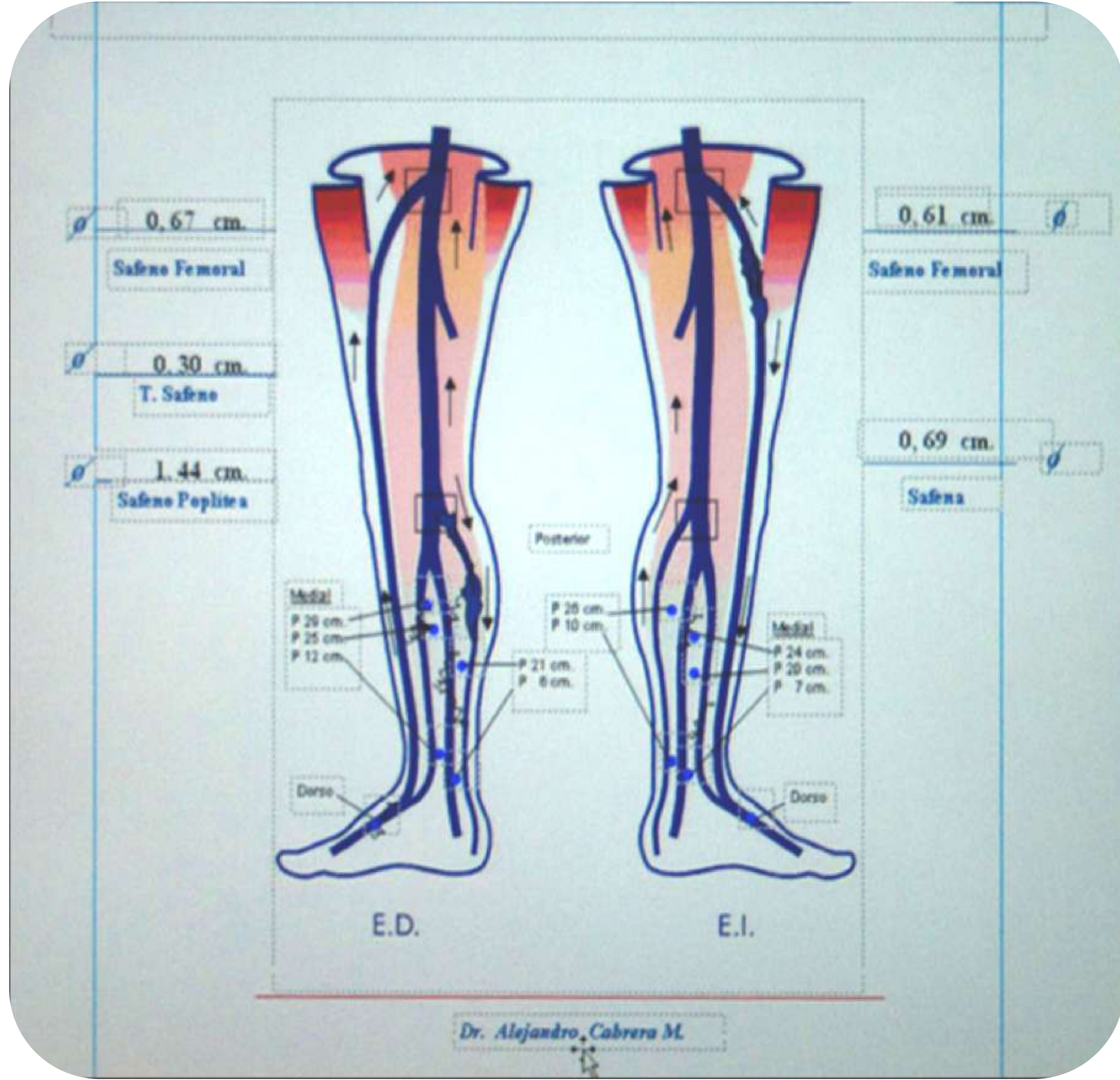








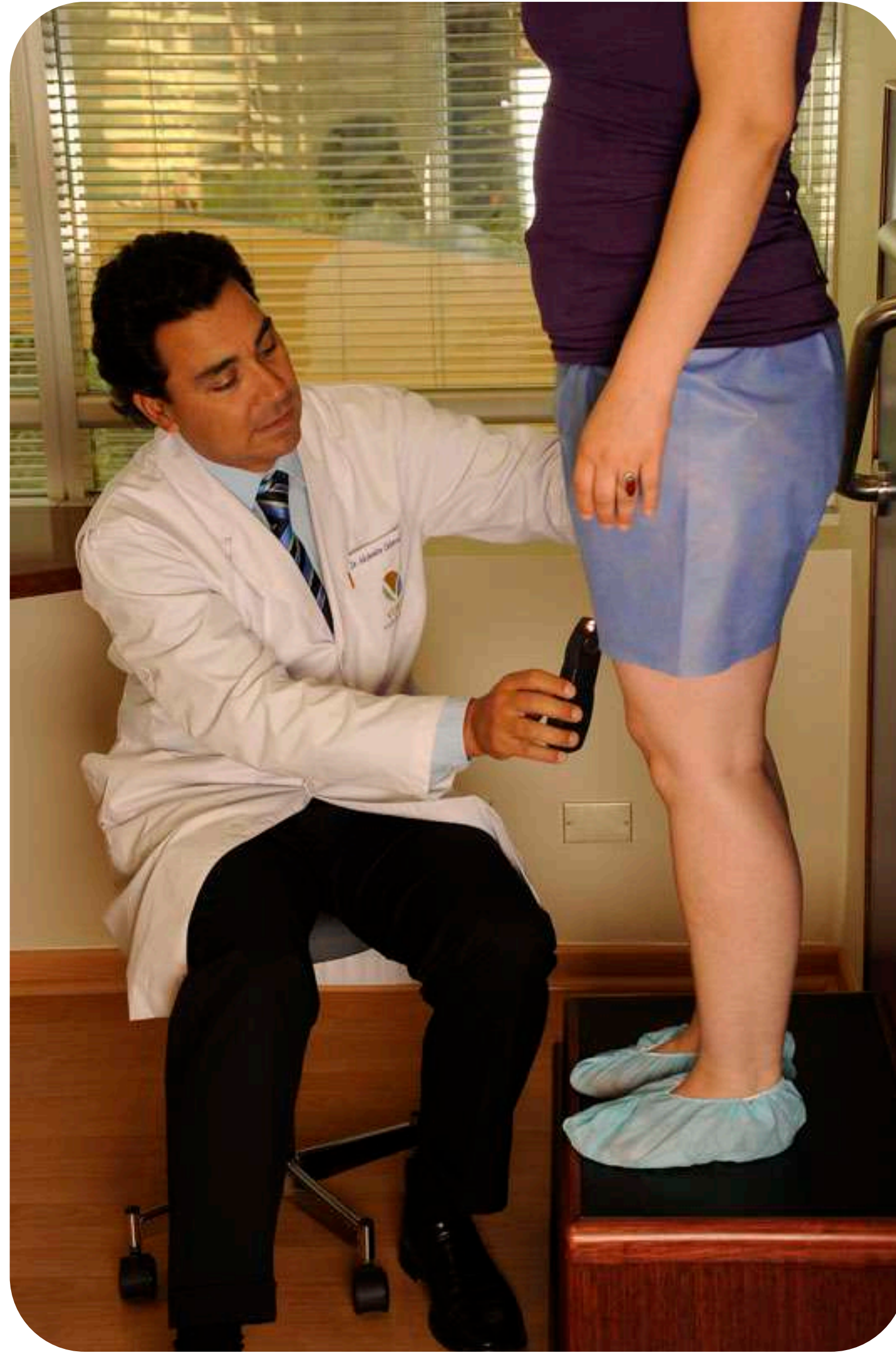


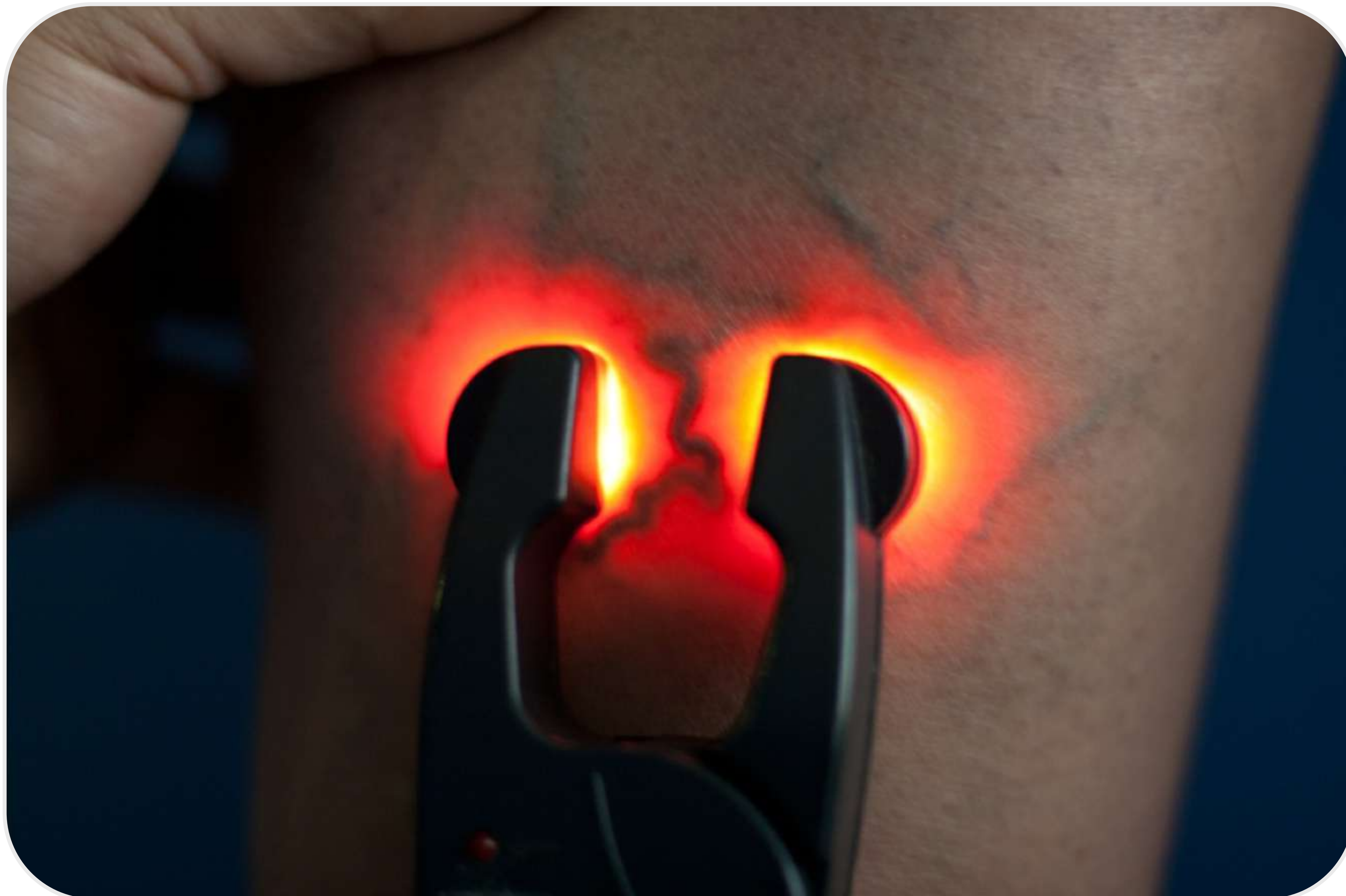

Dr. Alejandro Cabrera M.

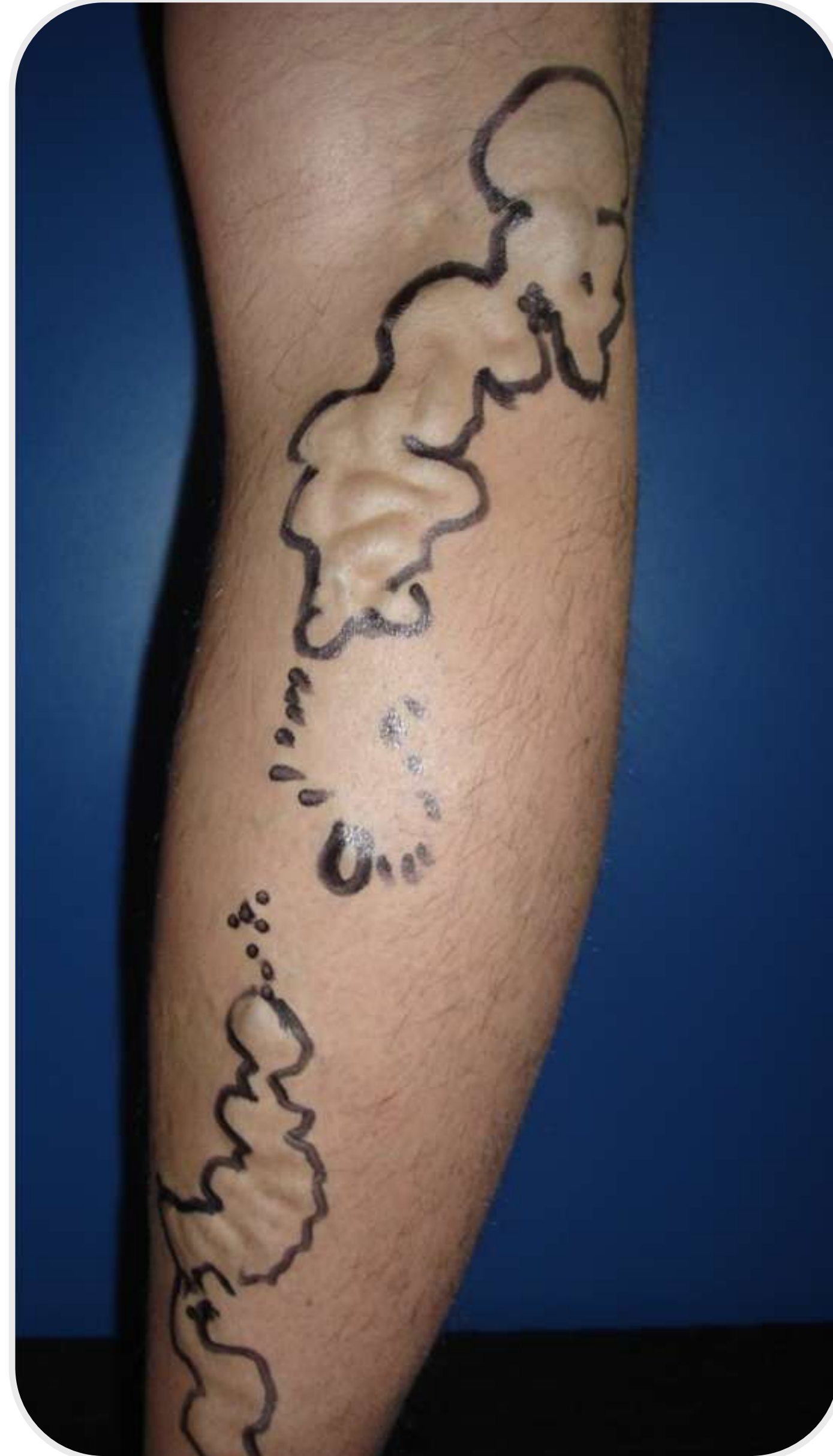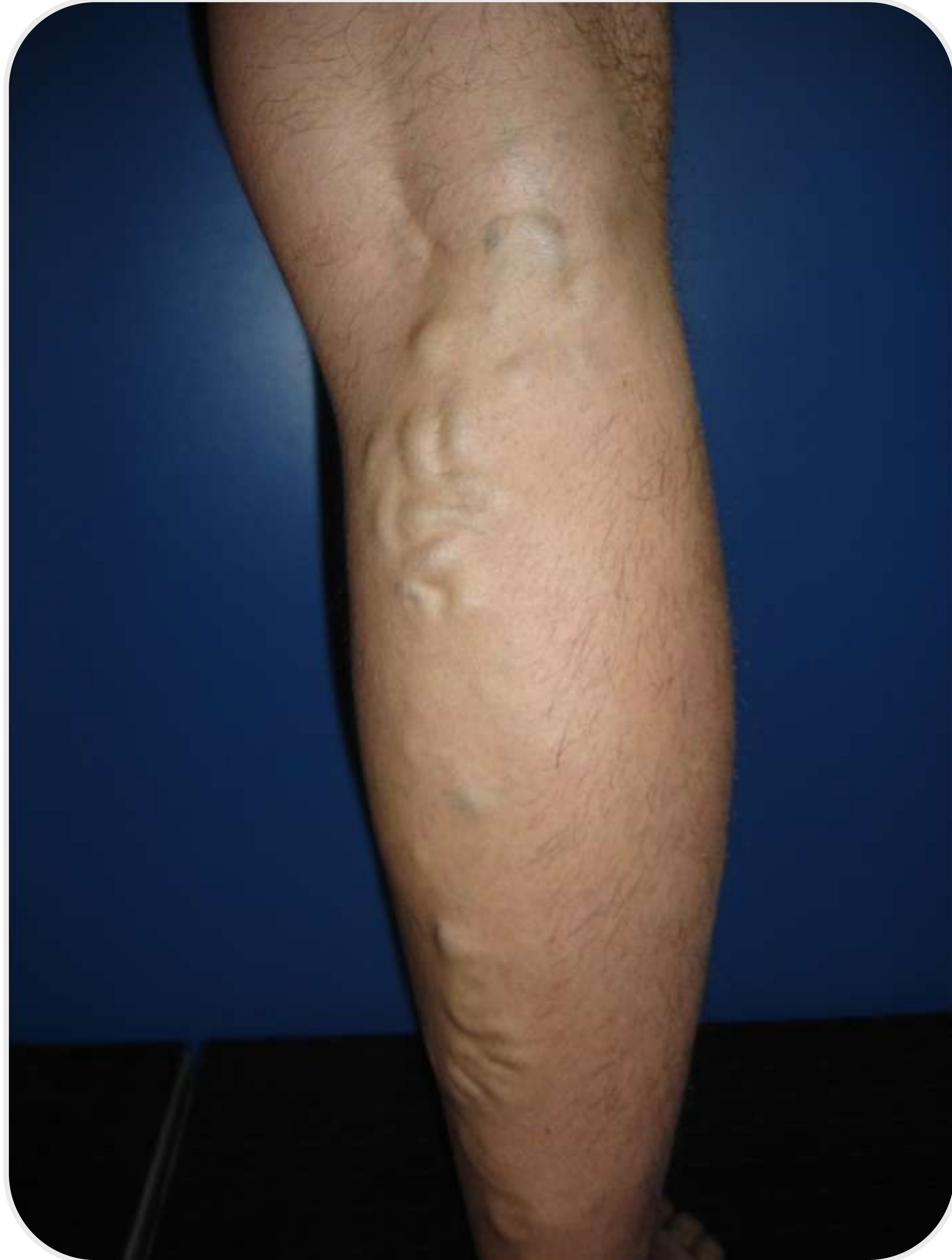Dr. Alejandro Cabrera M.

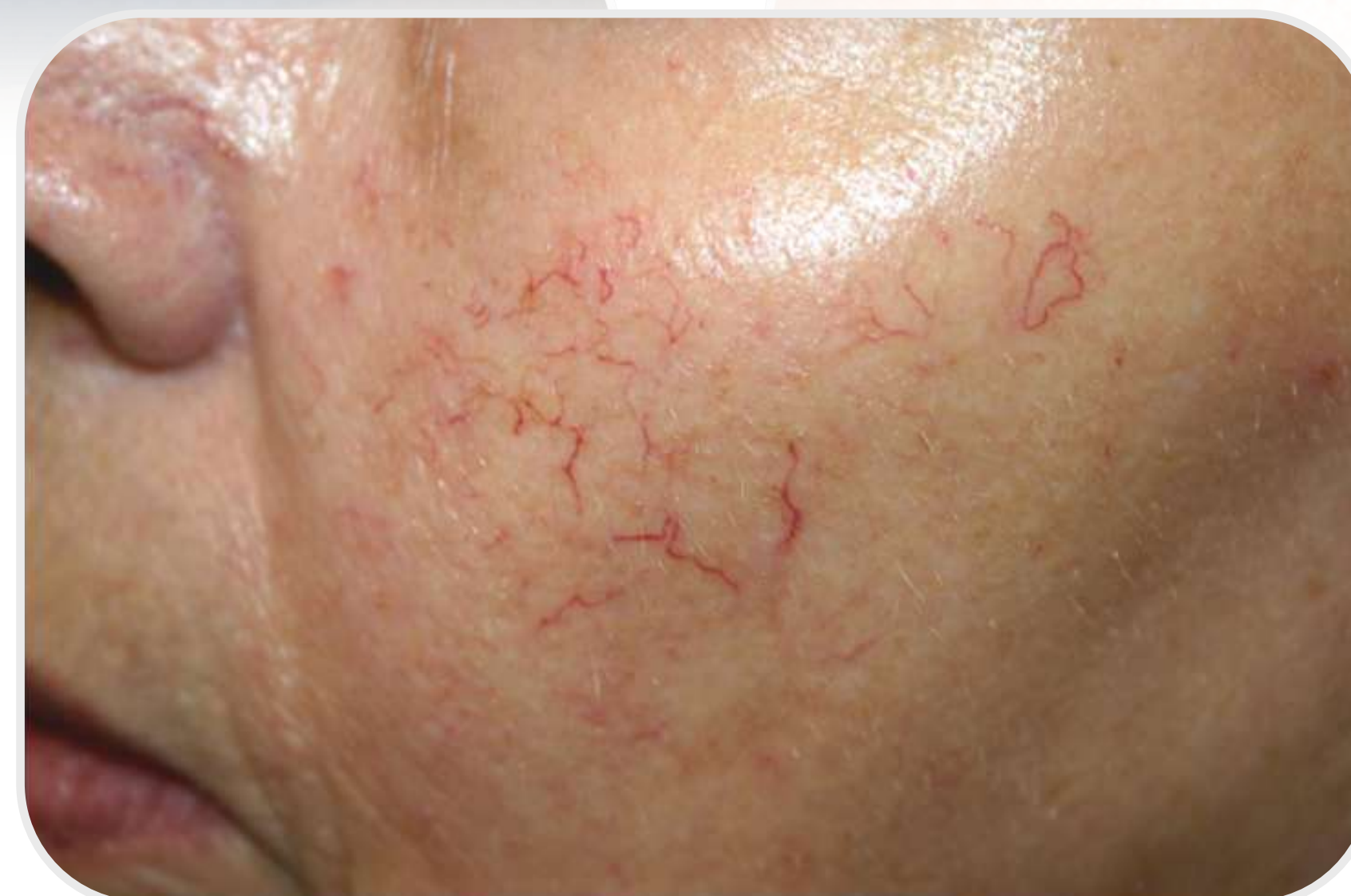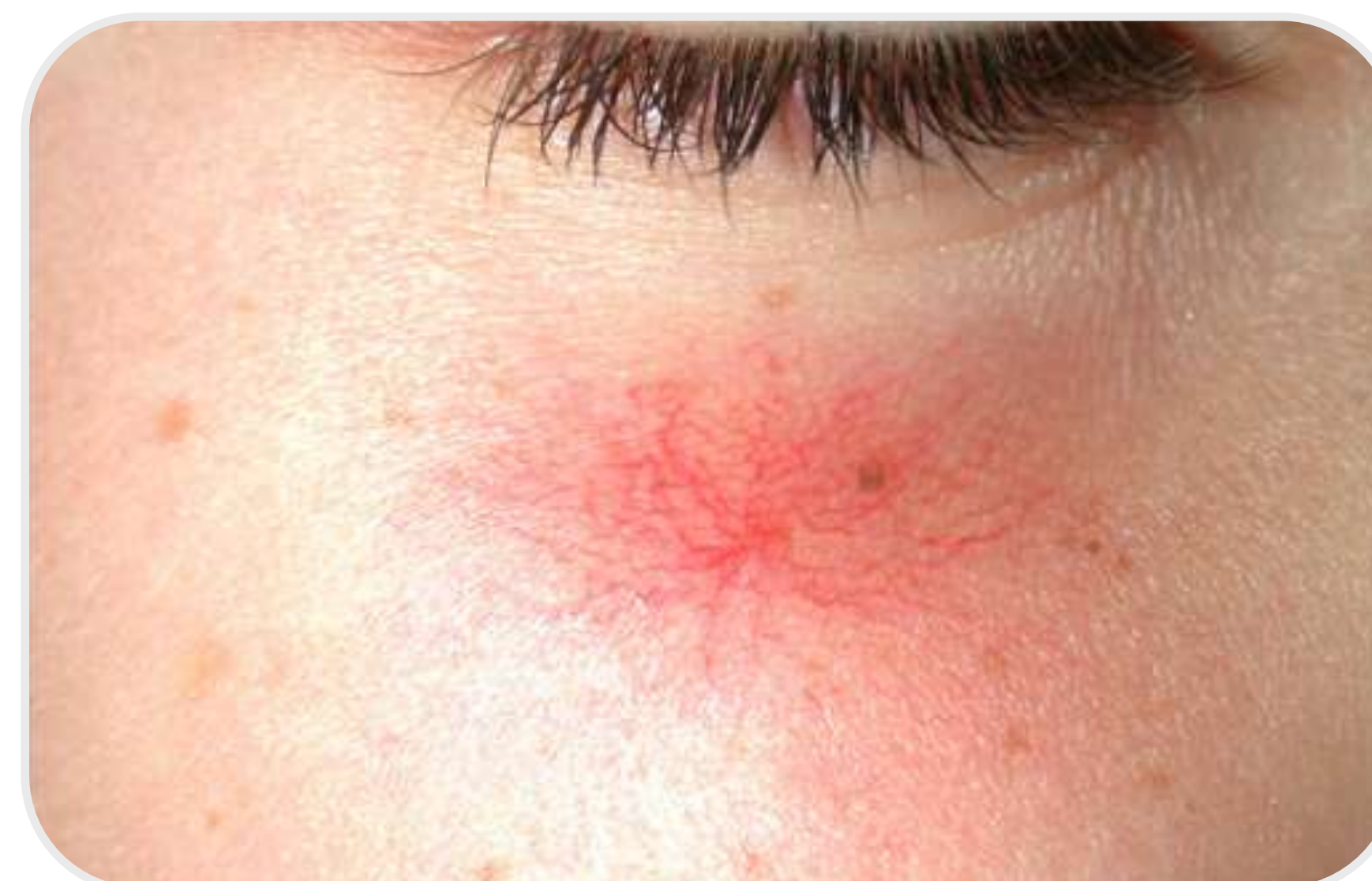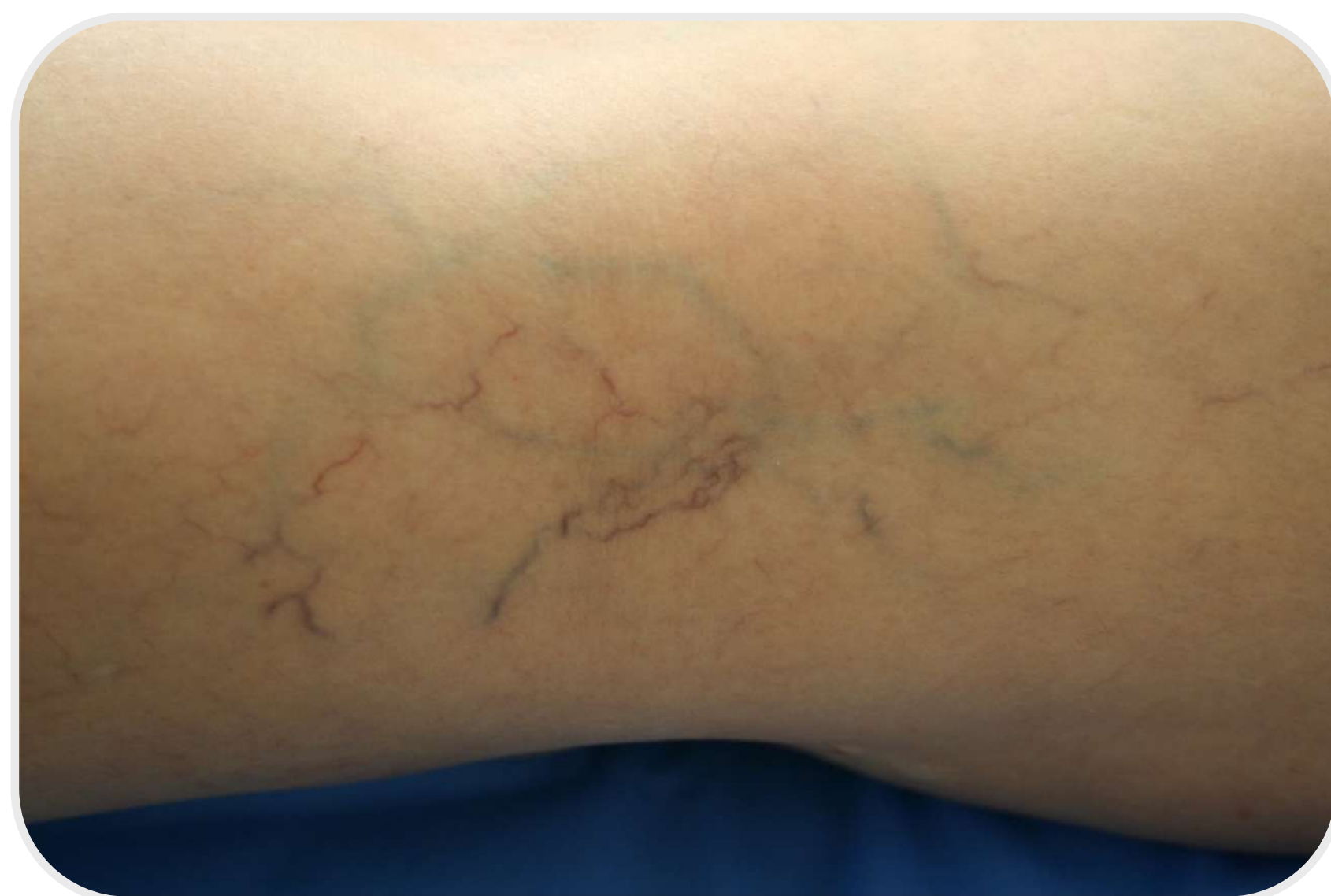# Examen físico

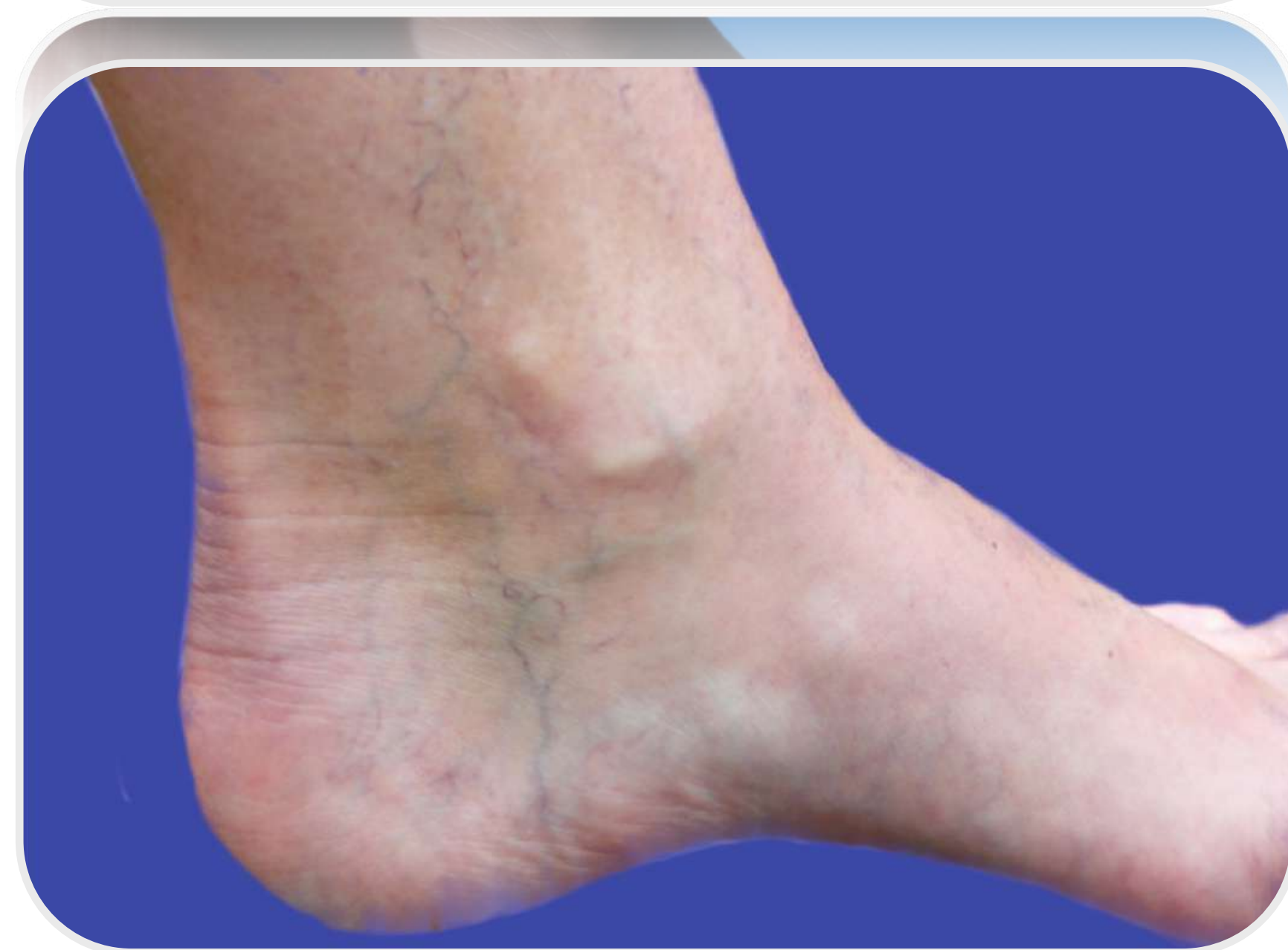
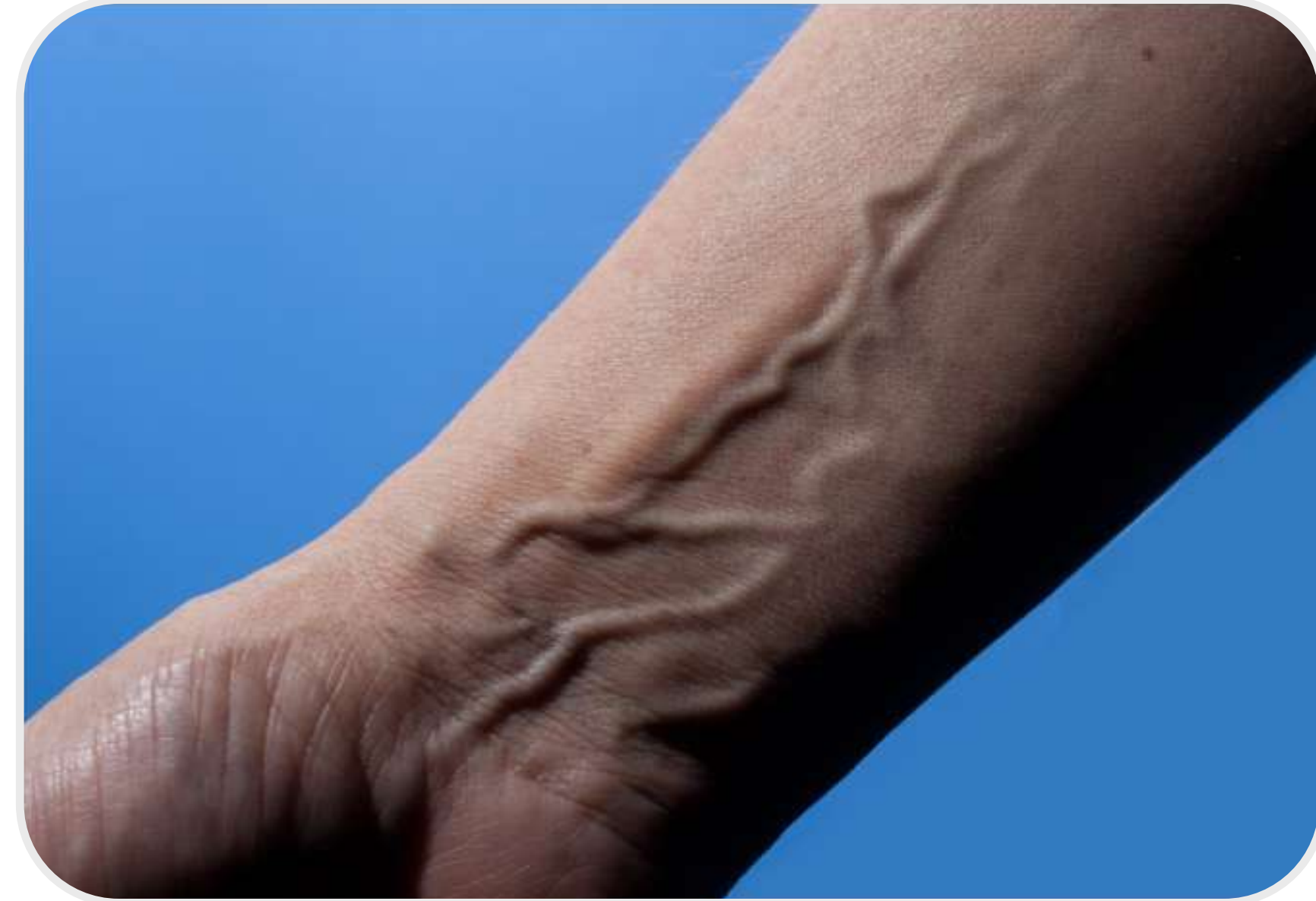
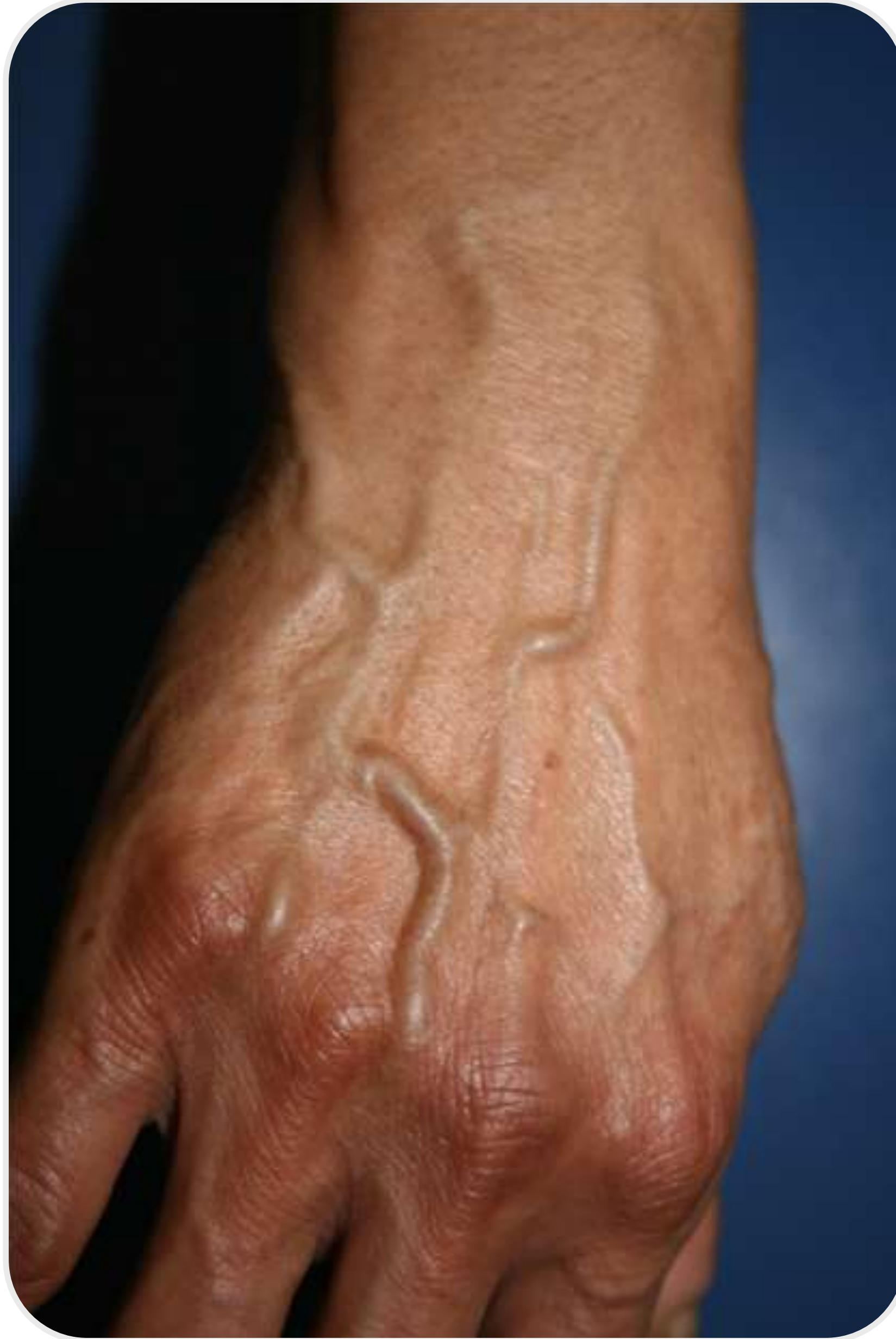







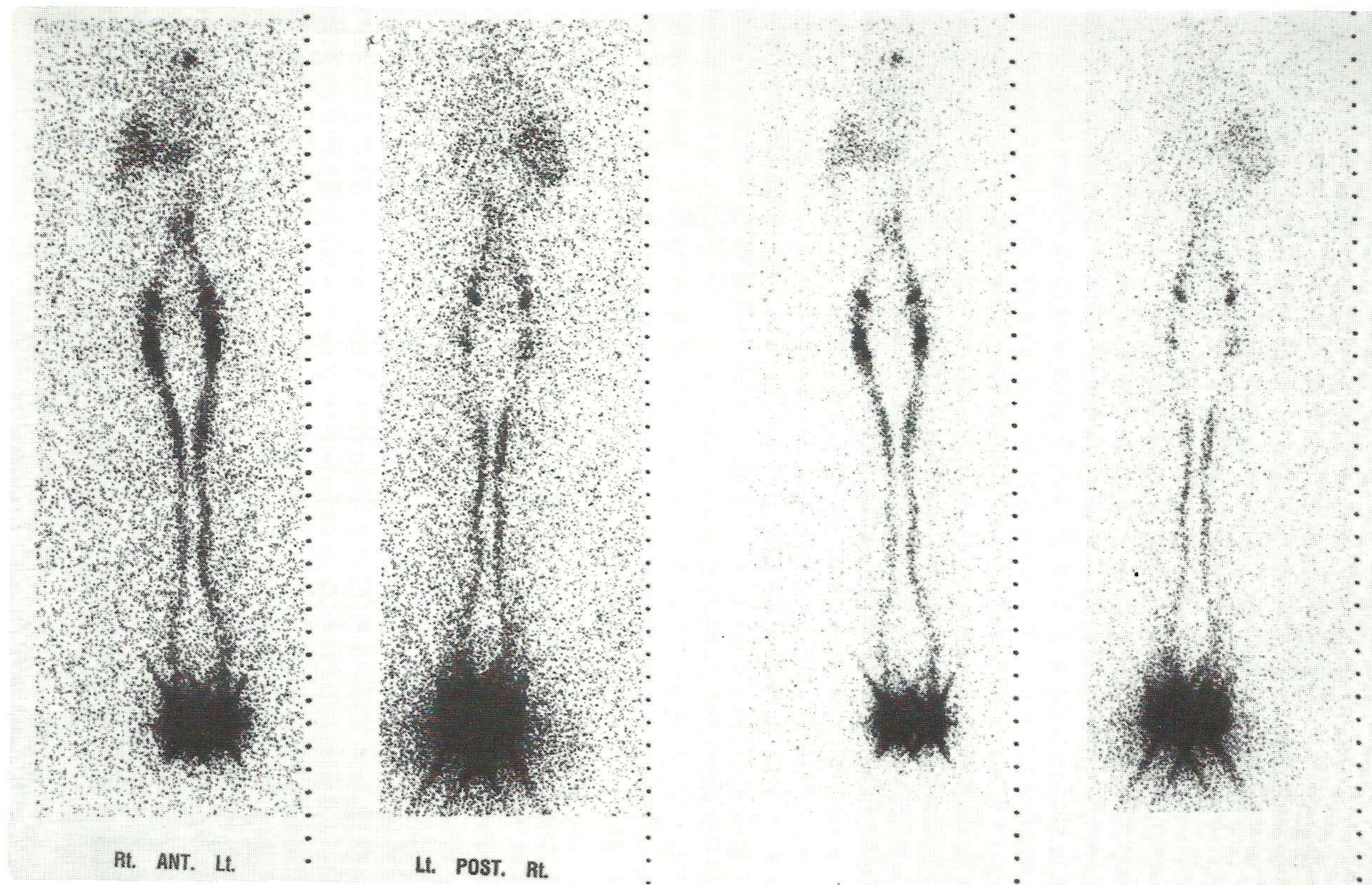


# SISTEMA LINFÁTICO

# SISTEMA LINFÁTICO

Dinámica de flujo y presiones

# Linfocintigrafía Radioisotópica

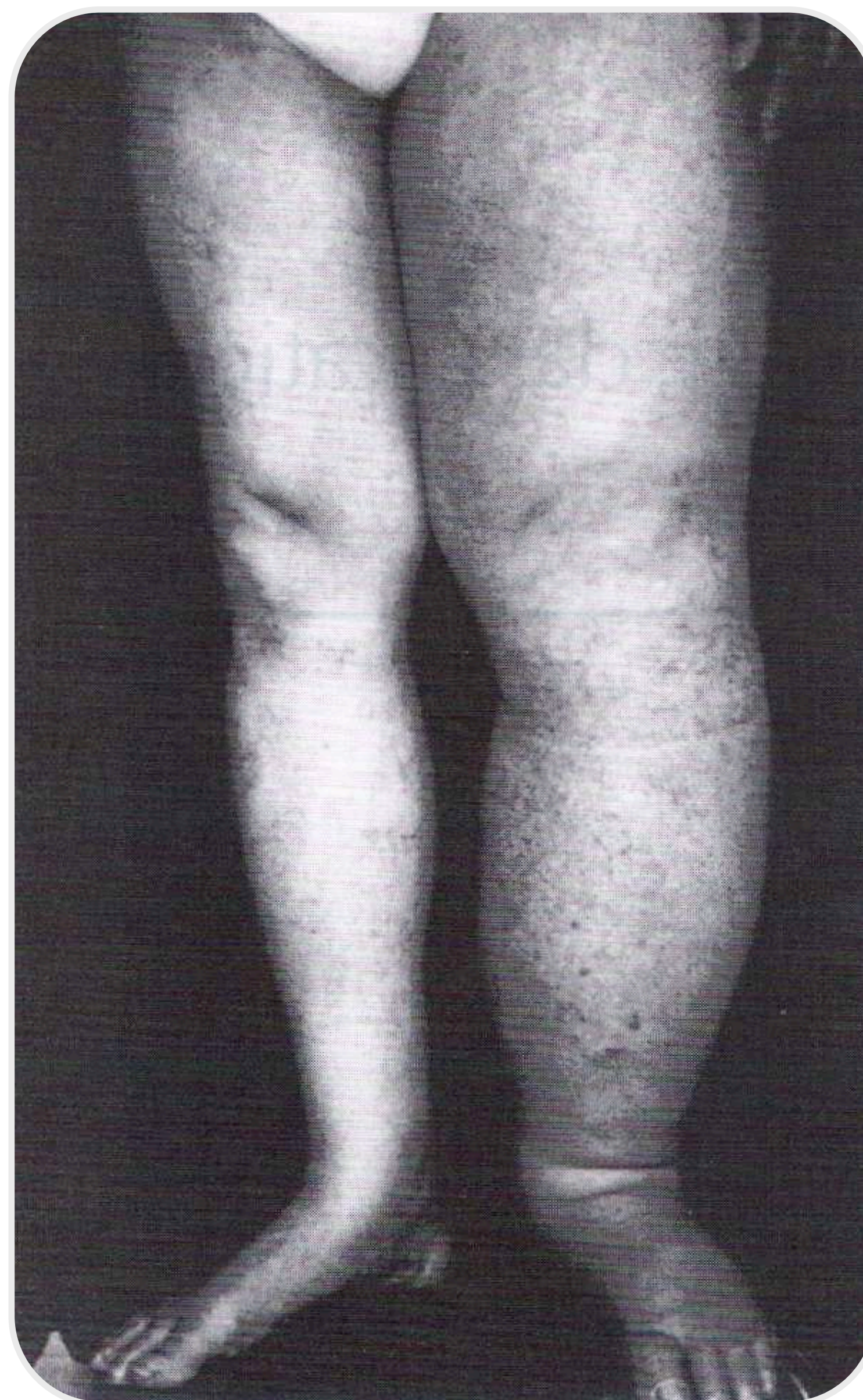


RL ANT. LL

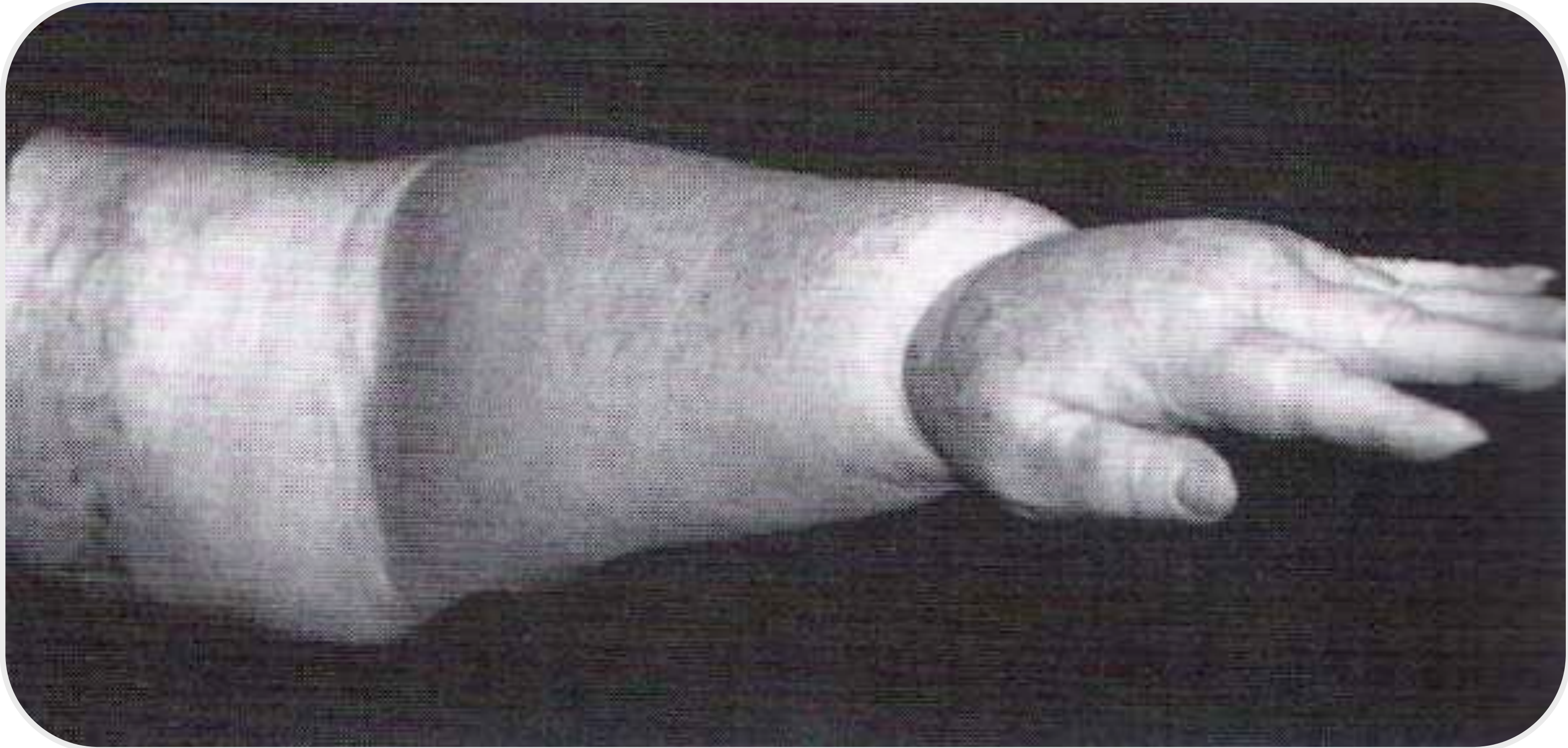
LL POST. RL

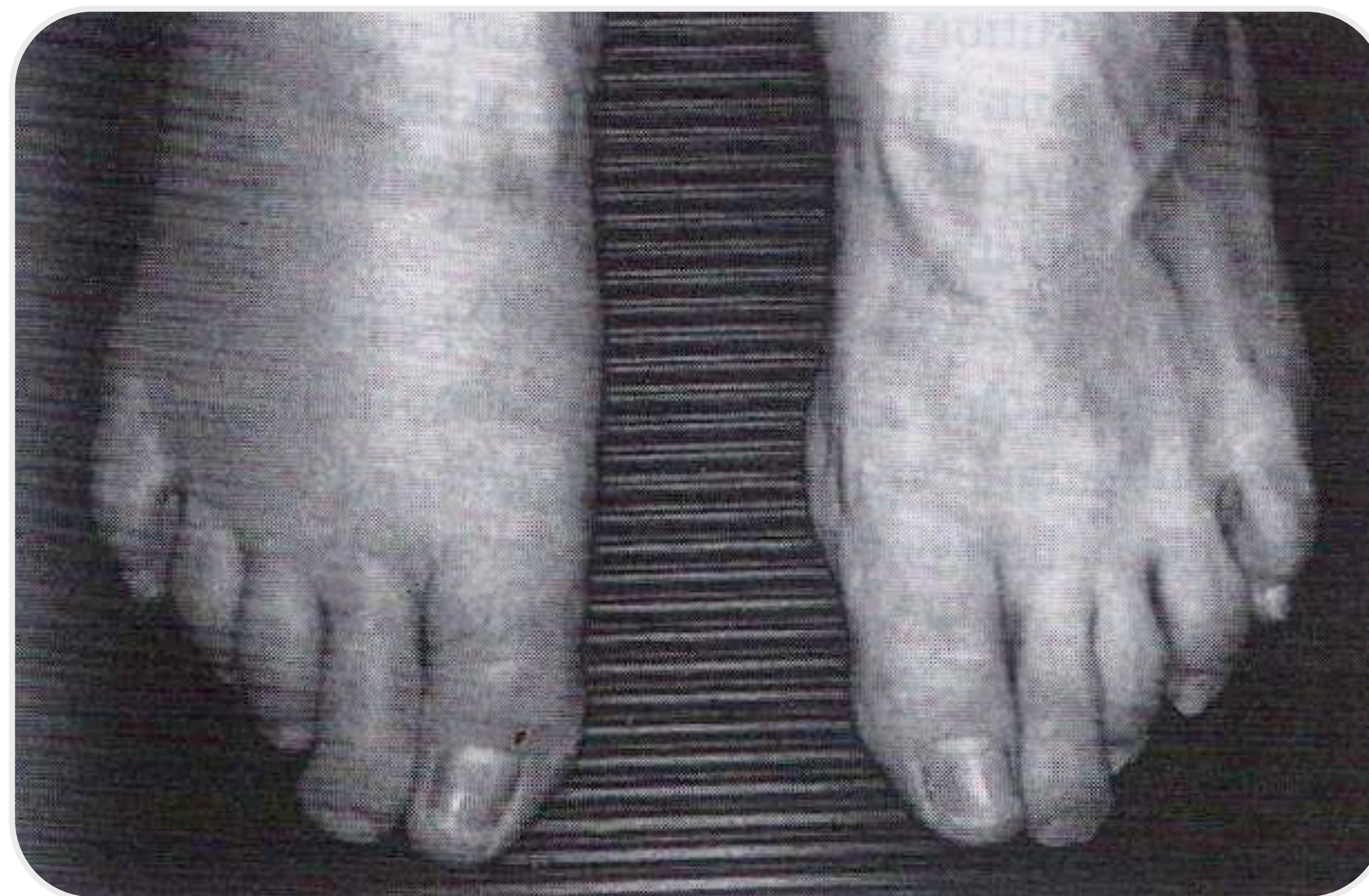
LL ANT. RL

RL POST. LL









# Anatomía Venosa y Linfática Enfoque funcional

Dr. Alejandro Cabrera M.

[drcabrera@instituteofveintechnology.com](mailto:drcabrera@instituteofveintechnology.com)