

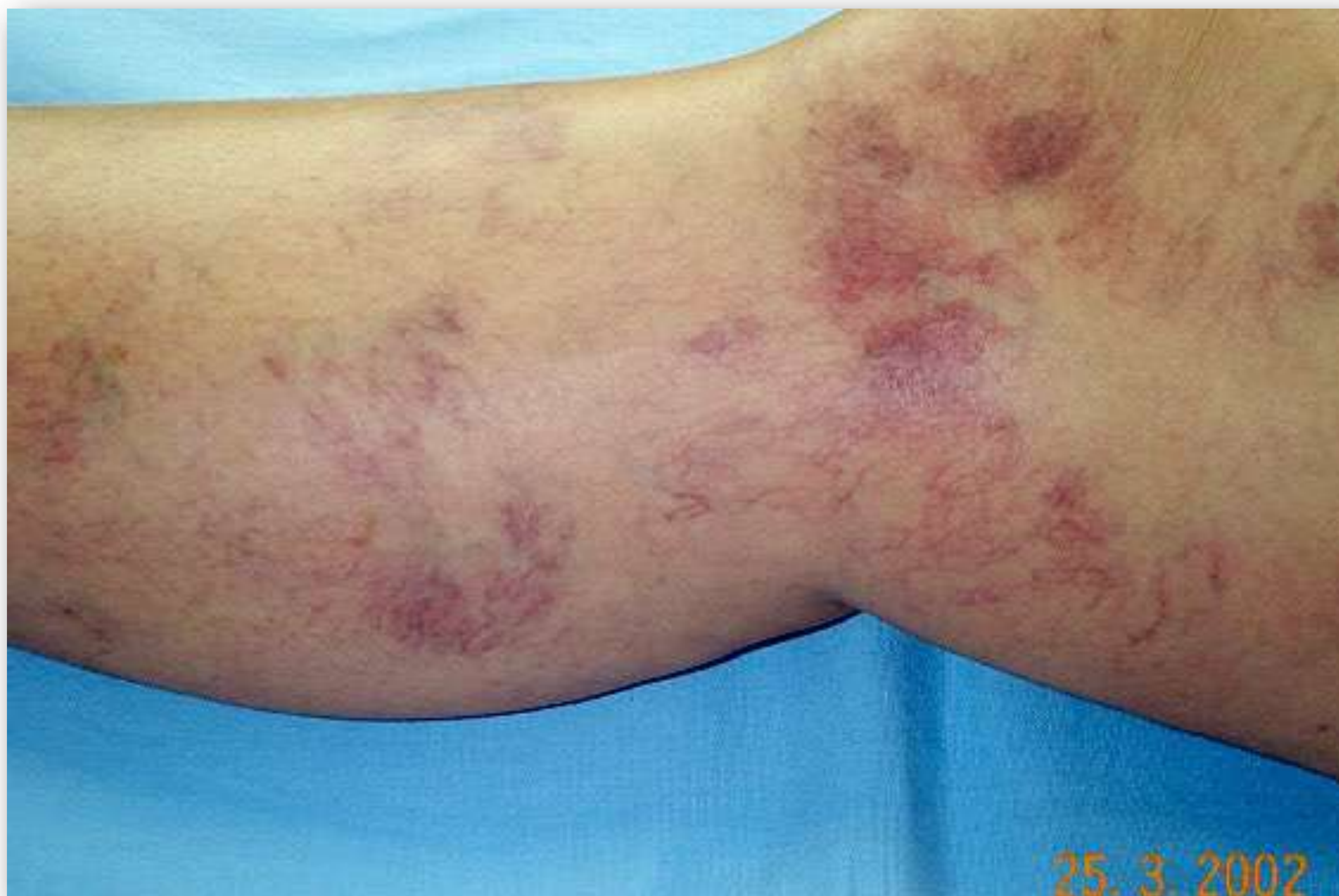Procedures III

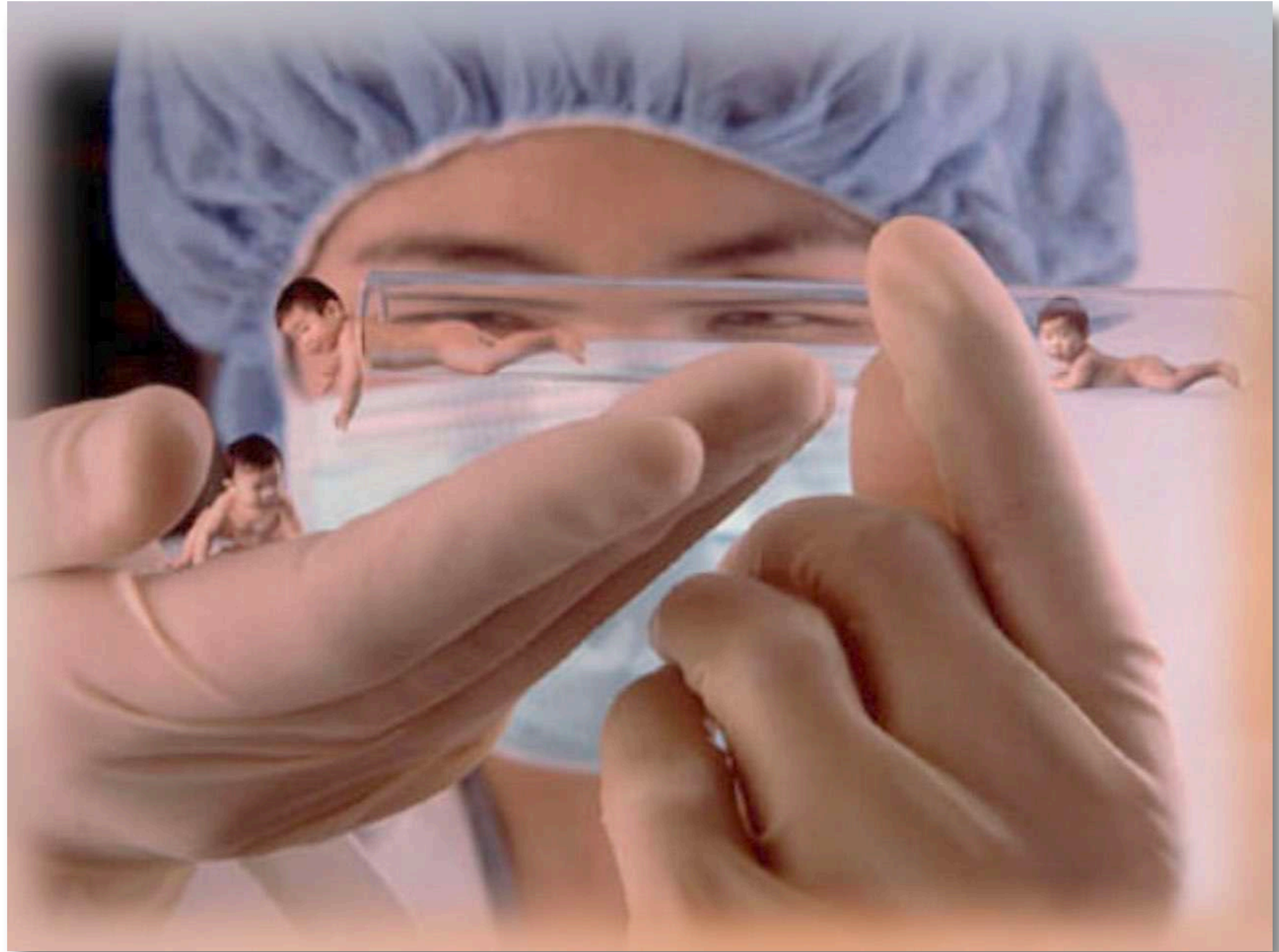Escleroterapia

VARICES RETICULARES

TELANGIECTASIAS

Dr. Alejandro Cabrera M.







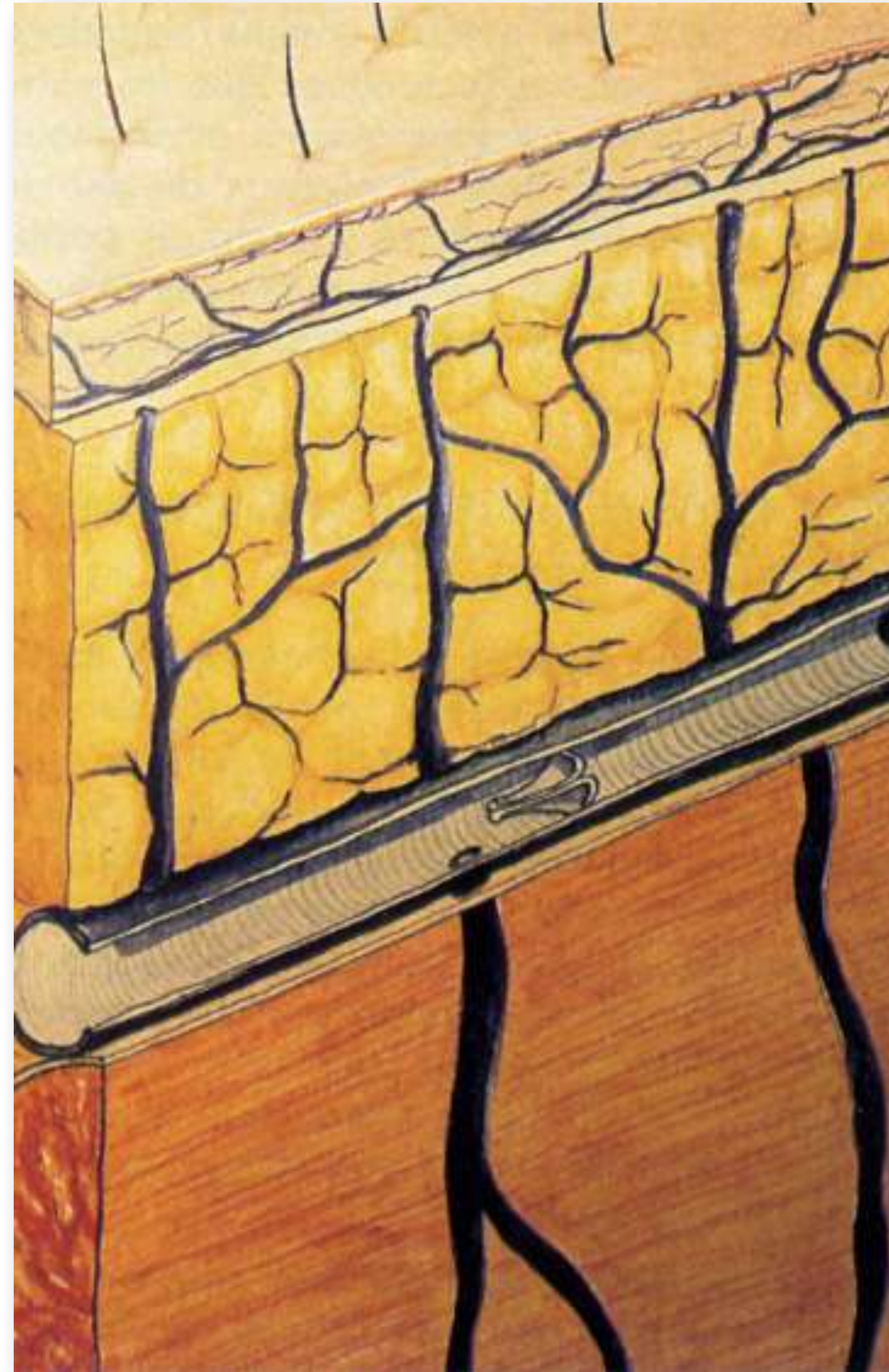METODOS DE ESCLEROTERAPIA

Definiciones

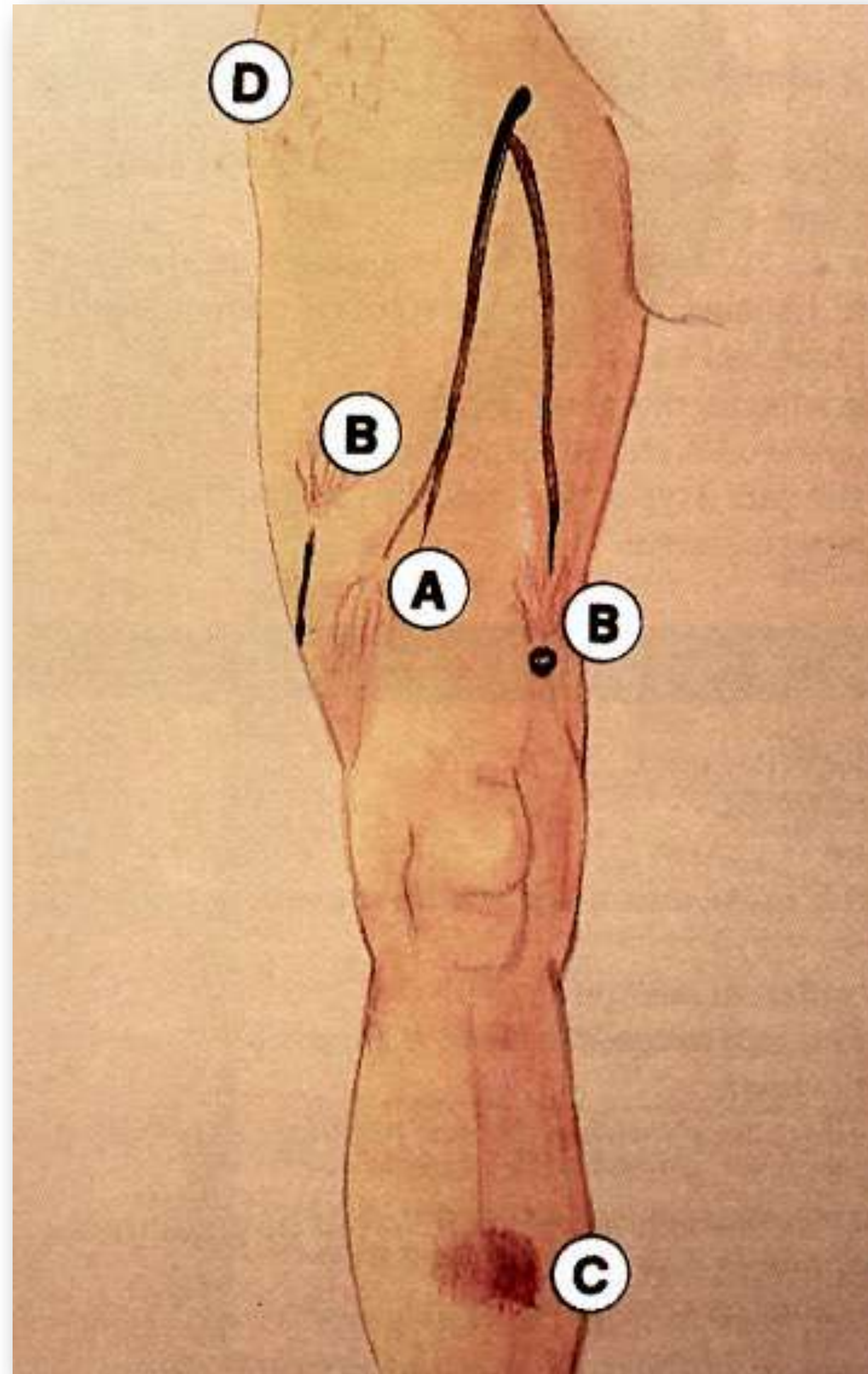
Telangiectasias 0.1 a 1 mm

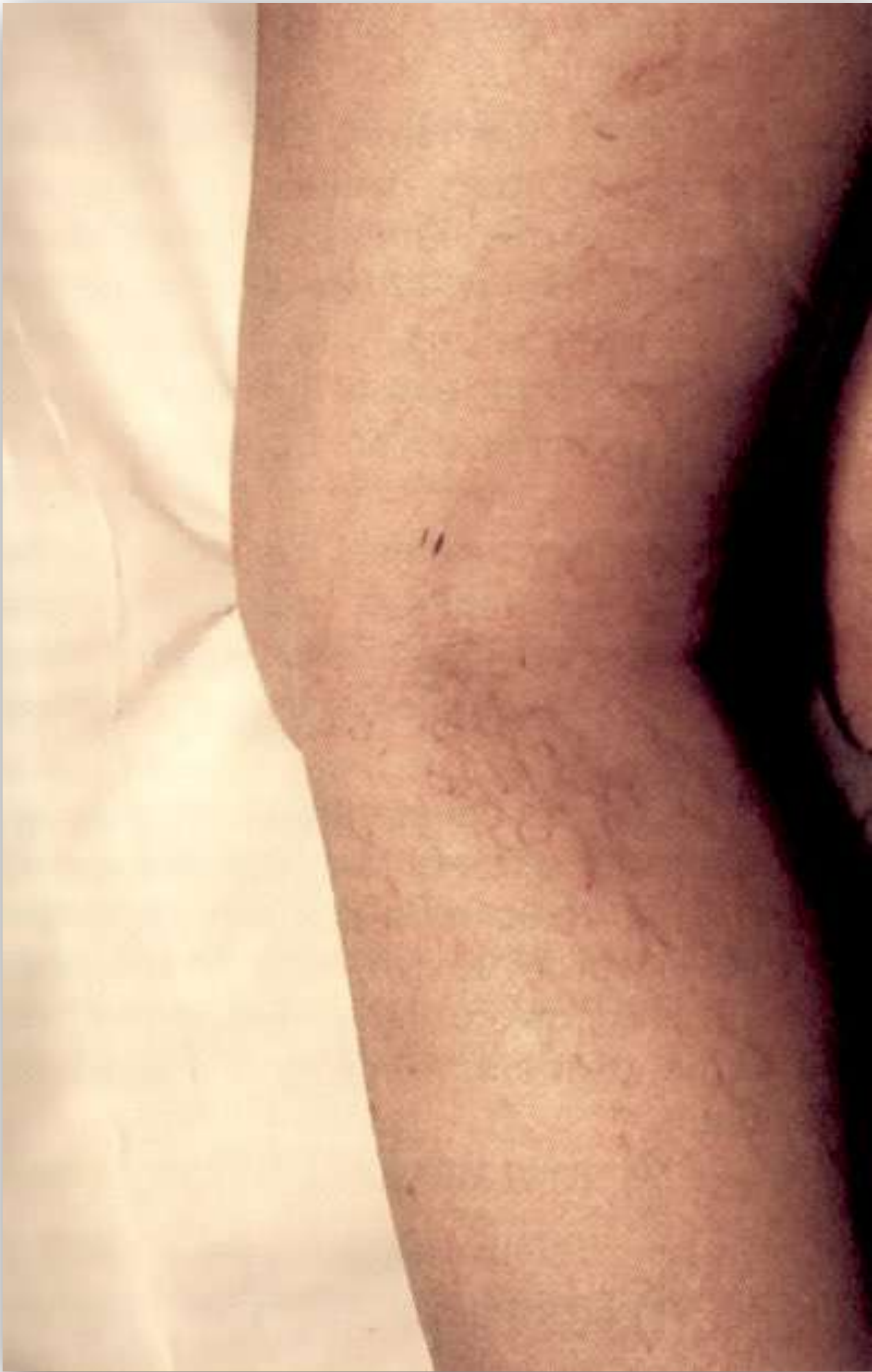Varices Reticulares 1 a 3 mm

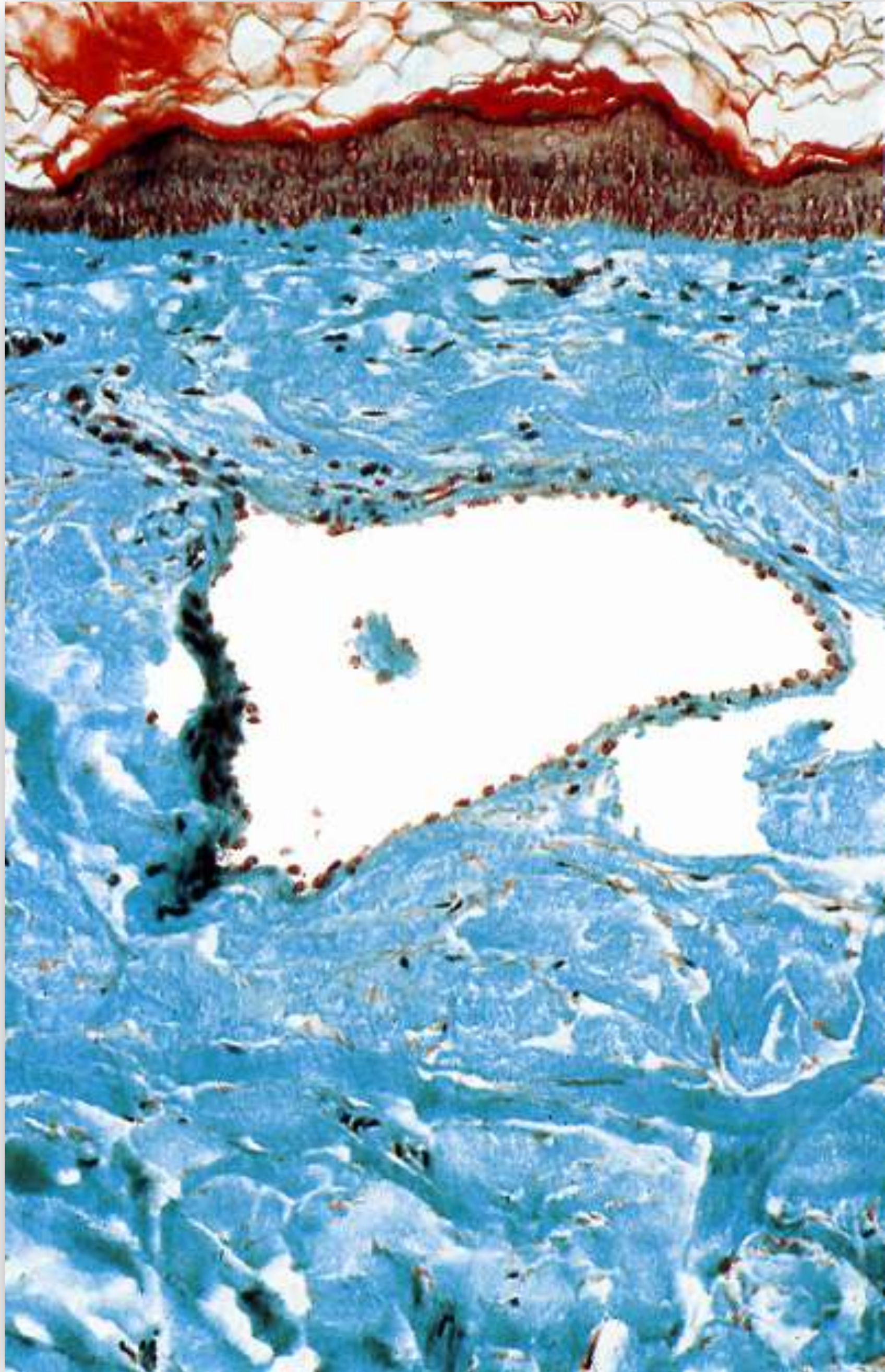
Varices Cordonales 3 mm o >



Feeding Vein







**¿ Microvarices aislados o asociados a
varices ?**

Estudio Flebológico

Ecomapeo venoso

¿Por qué un ecodoppler?

Estudio específico

Video-capilaroscopia

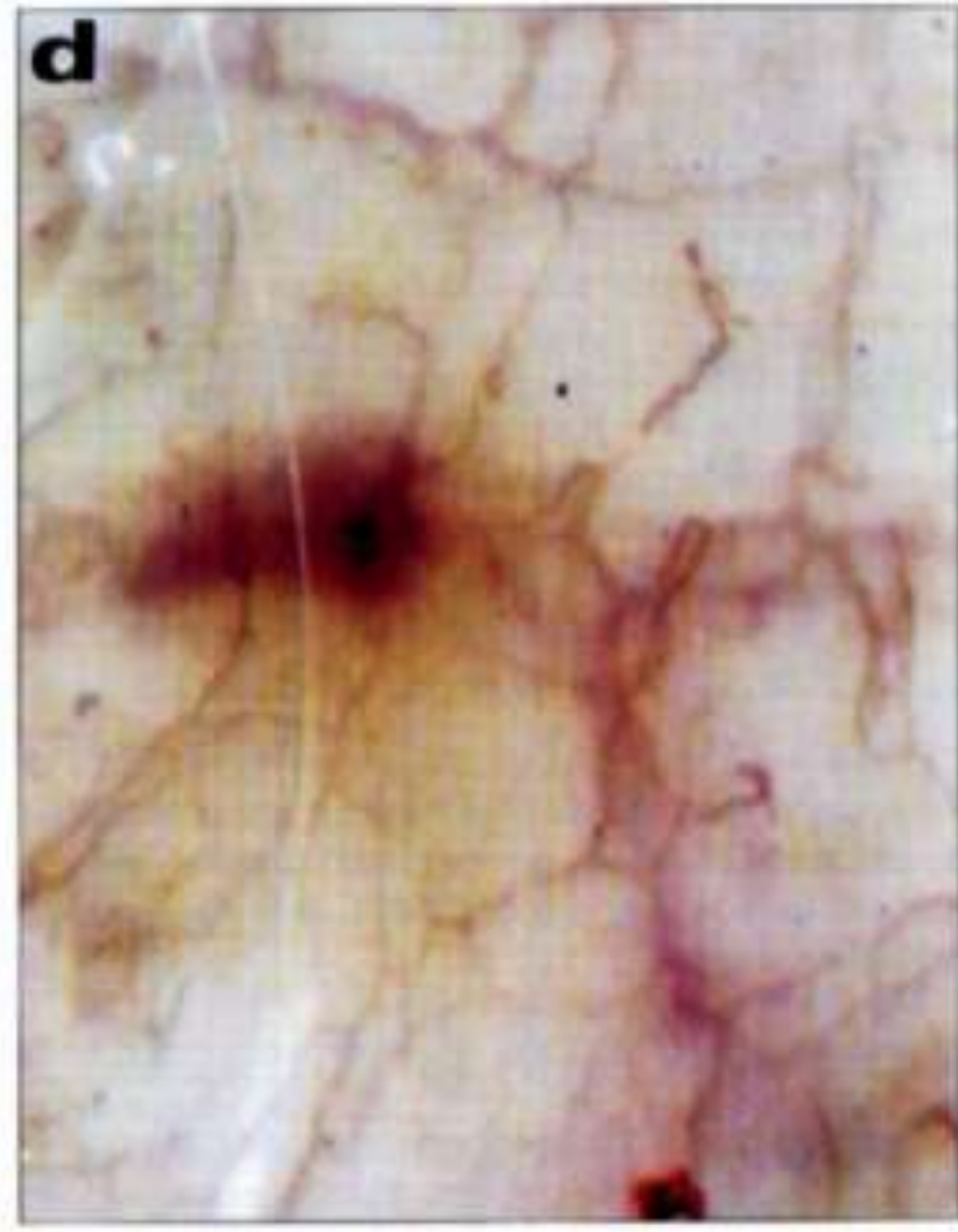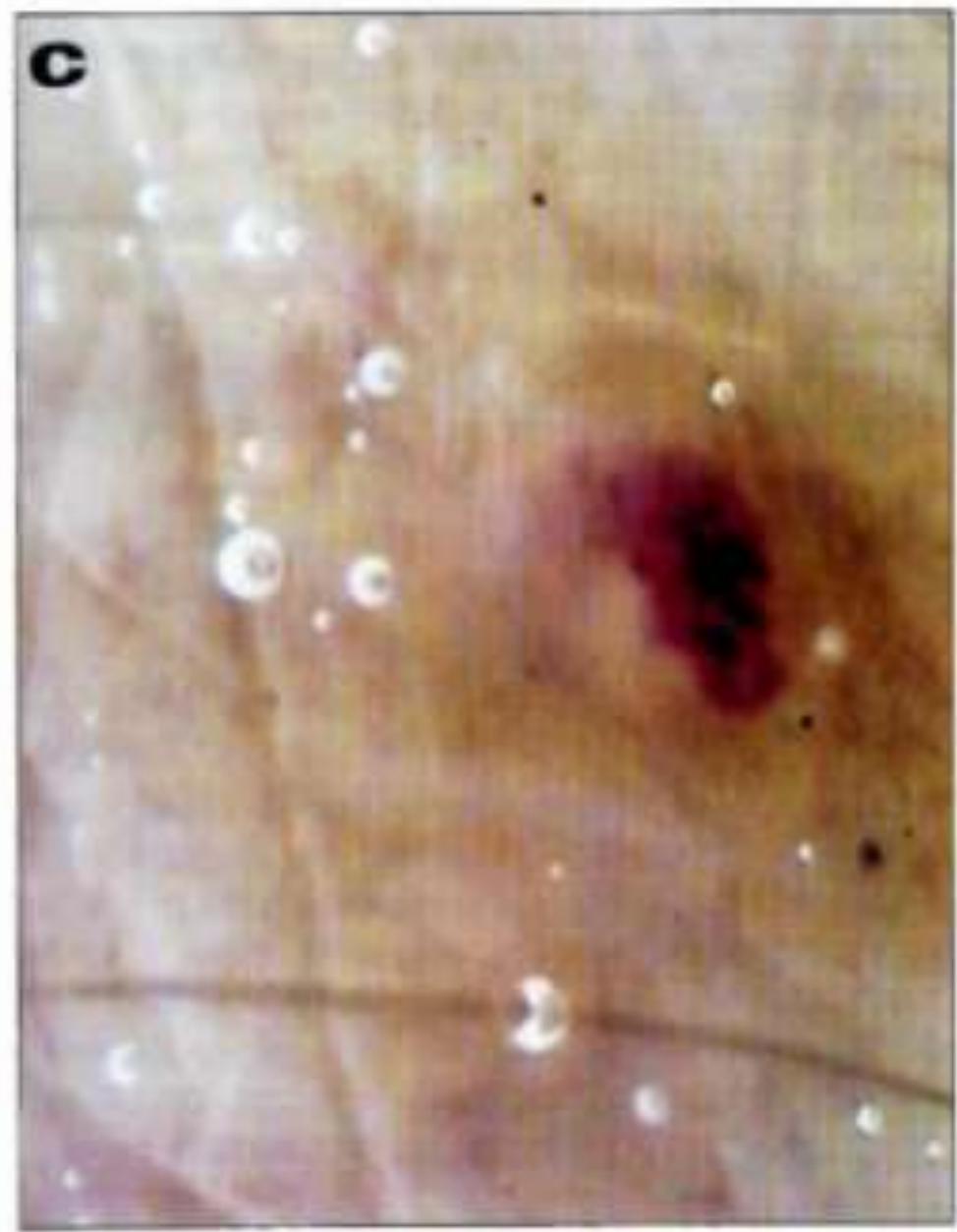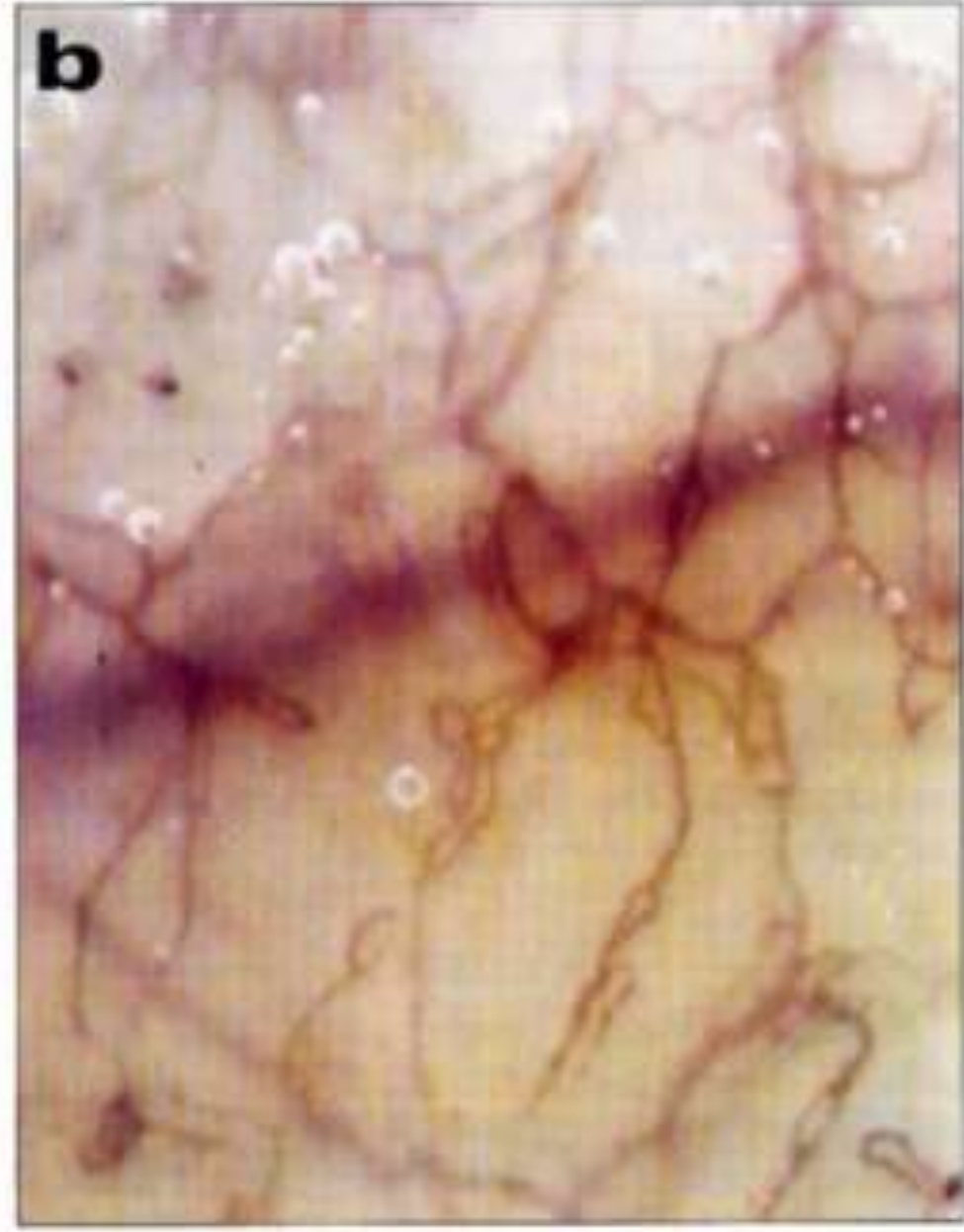
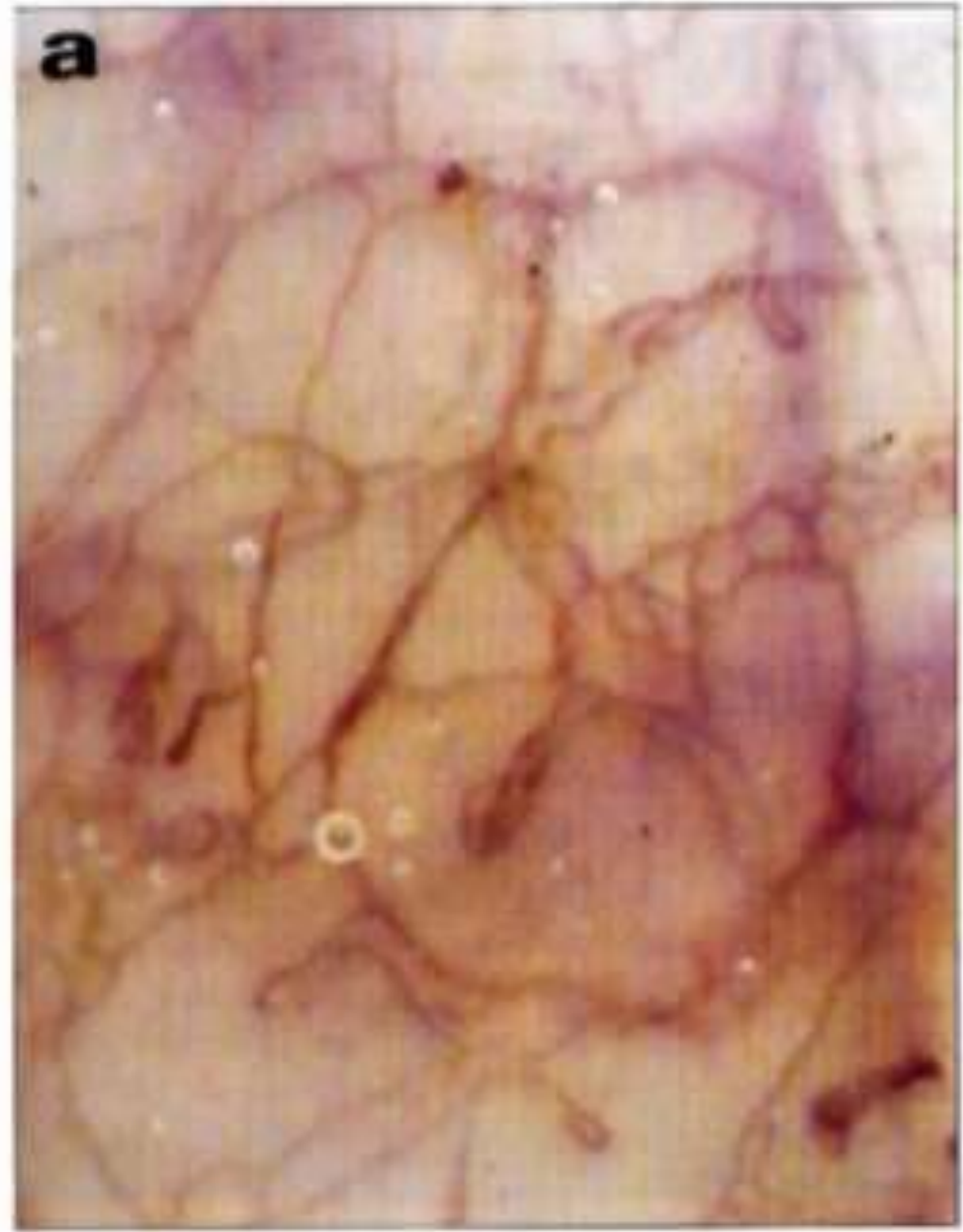
Ecodoppler (15 - 18 - 20 mhz)

Microflebografía

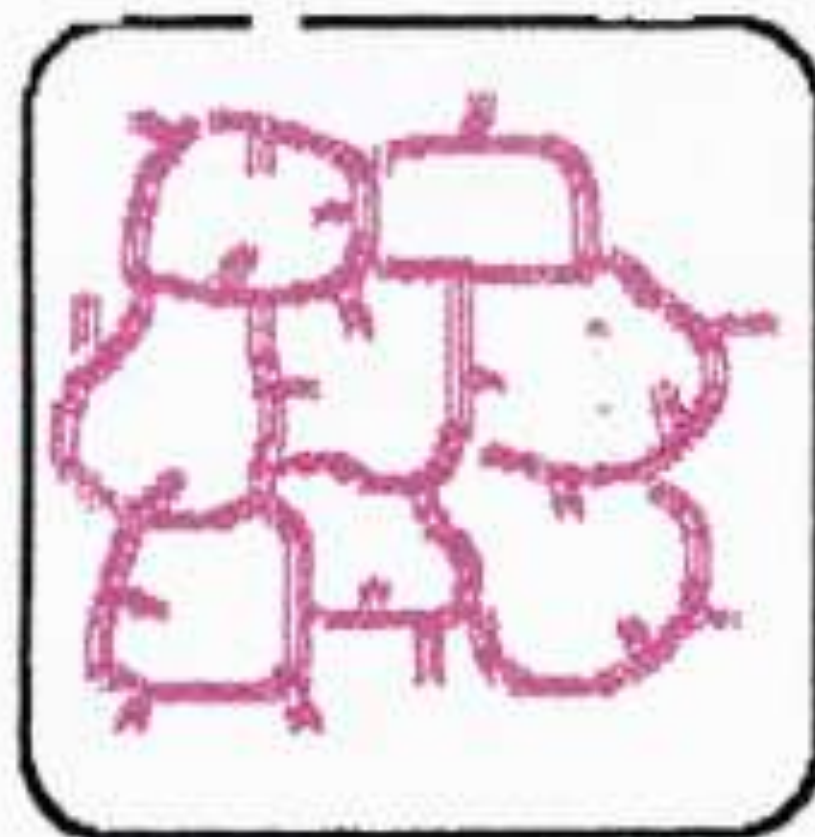
Espectrofotometría

Venoscopía

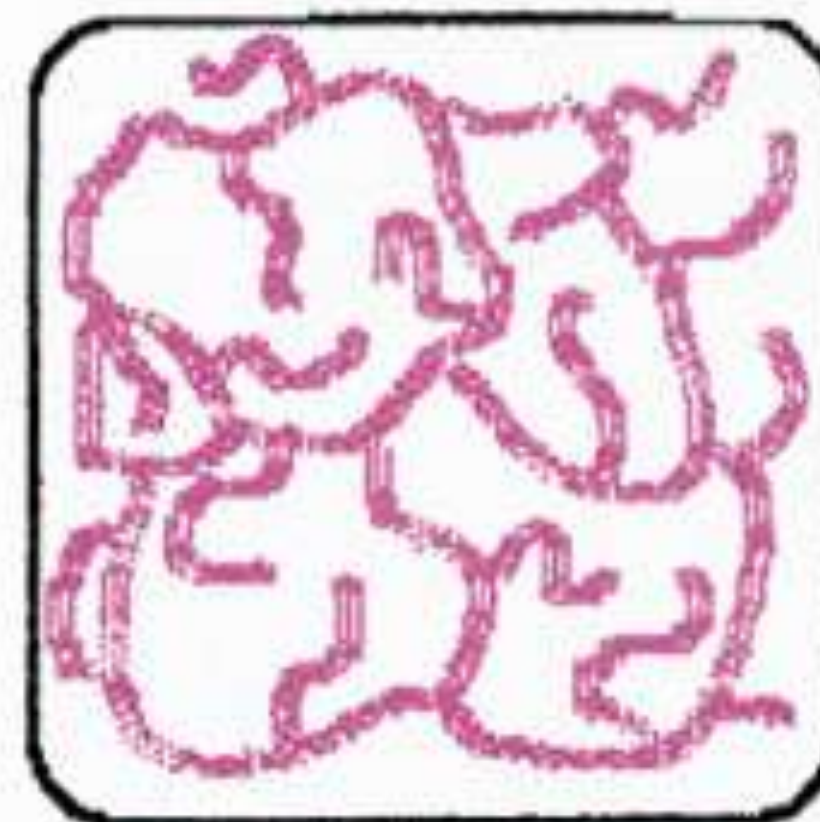
Protocolo Fotográfico



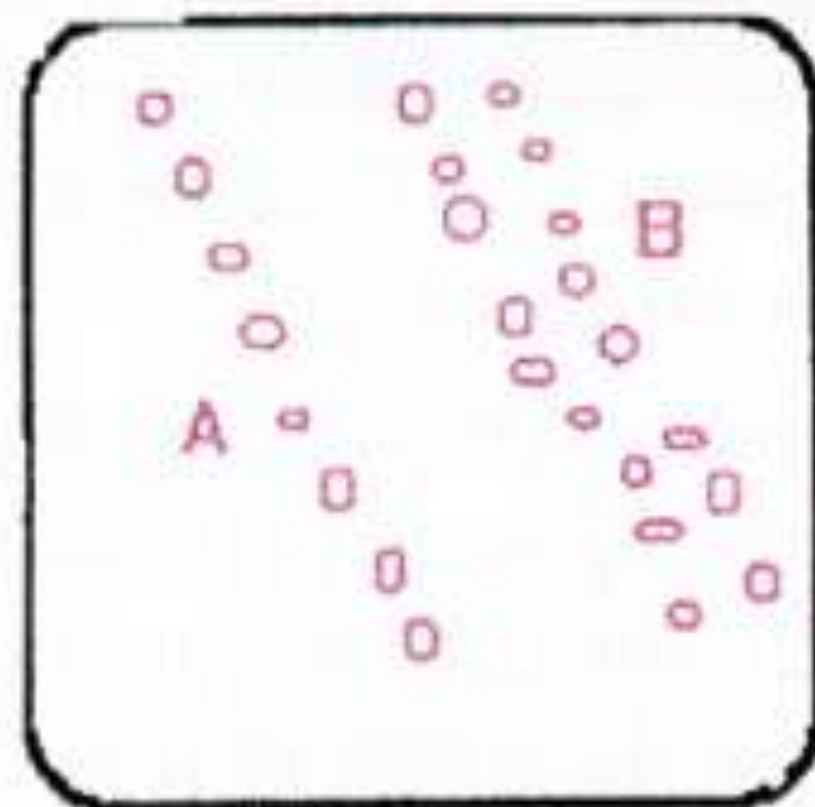
I Type, Groupe A



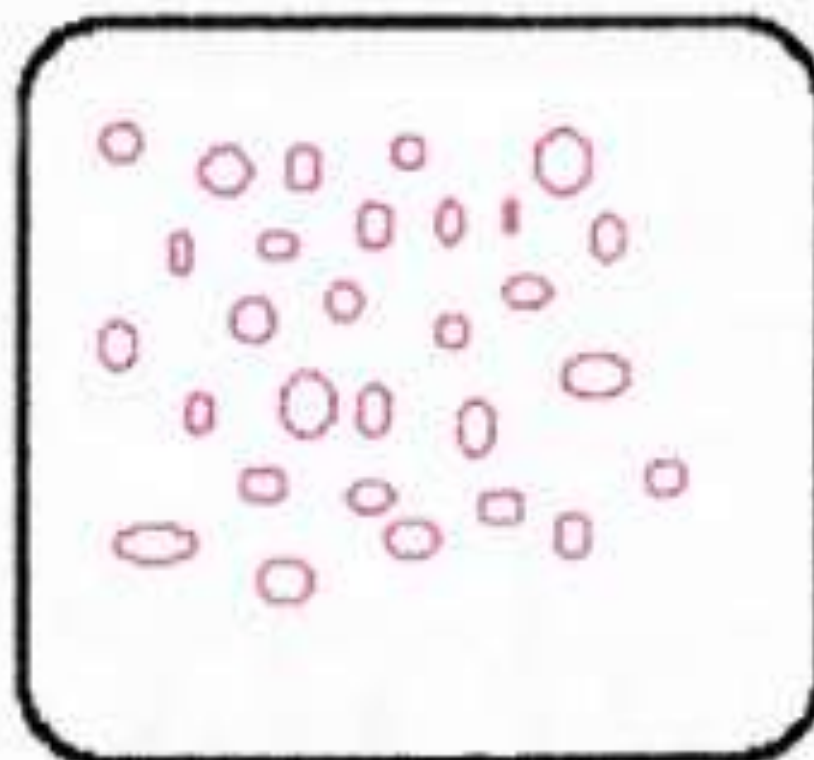
I Type, Groupe B



II Type, Groupe A

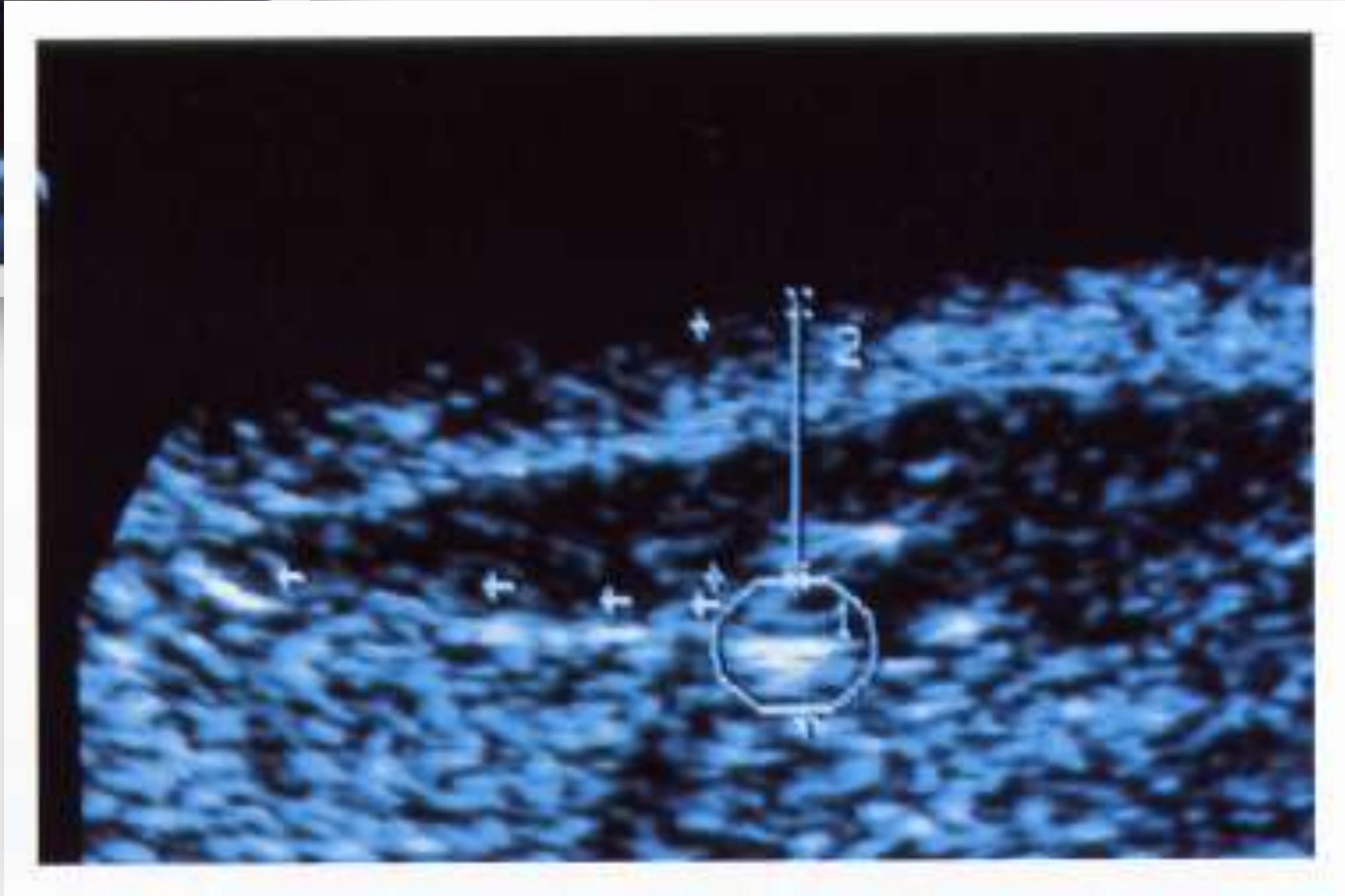
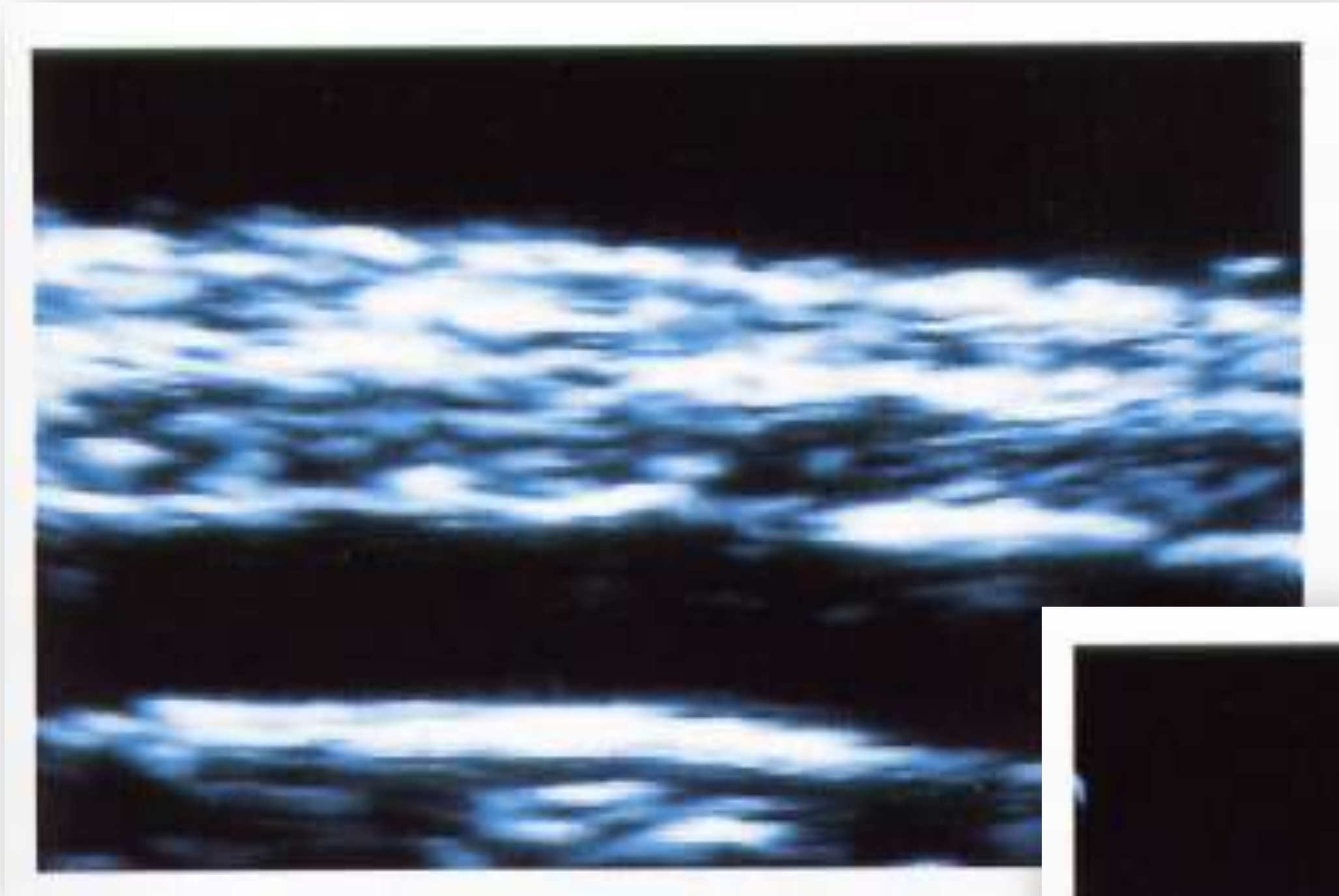


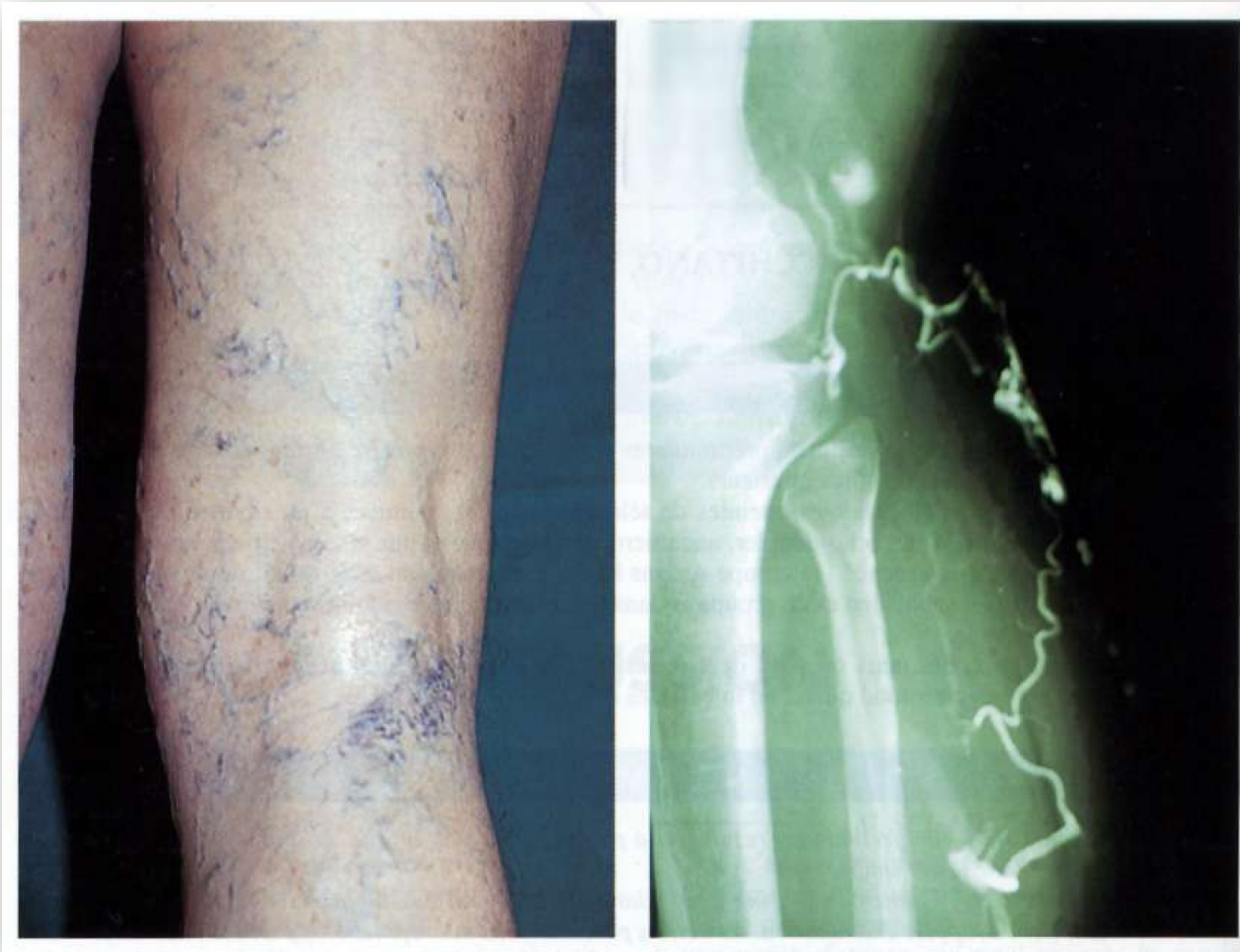II Type, groupe B

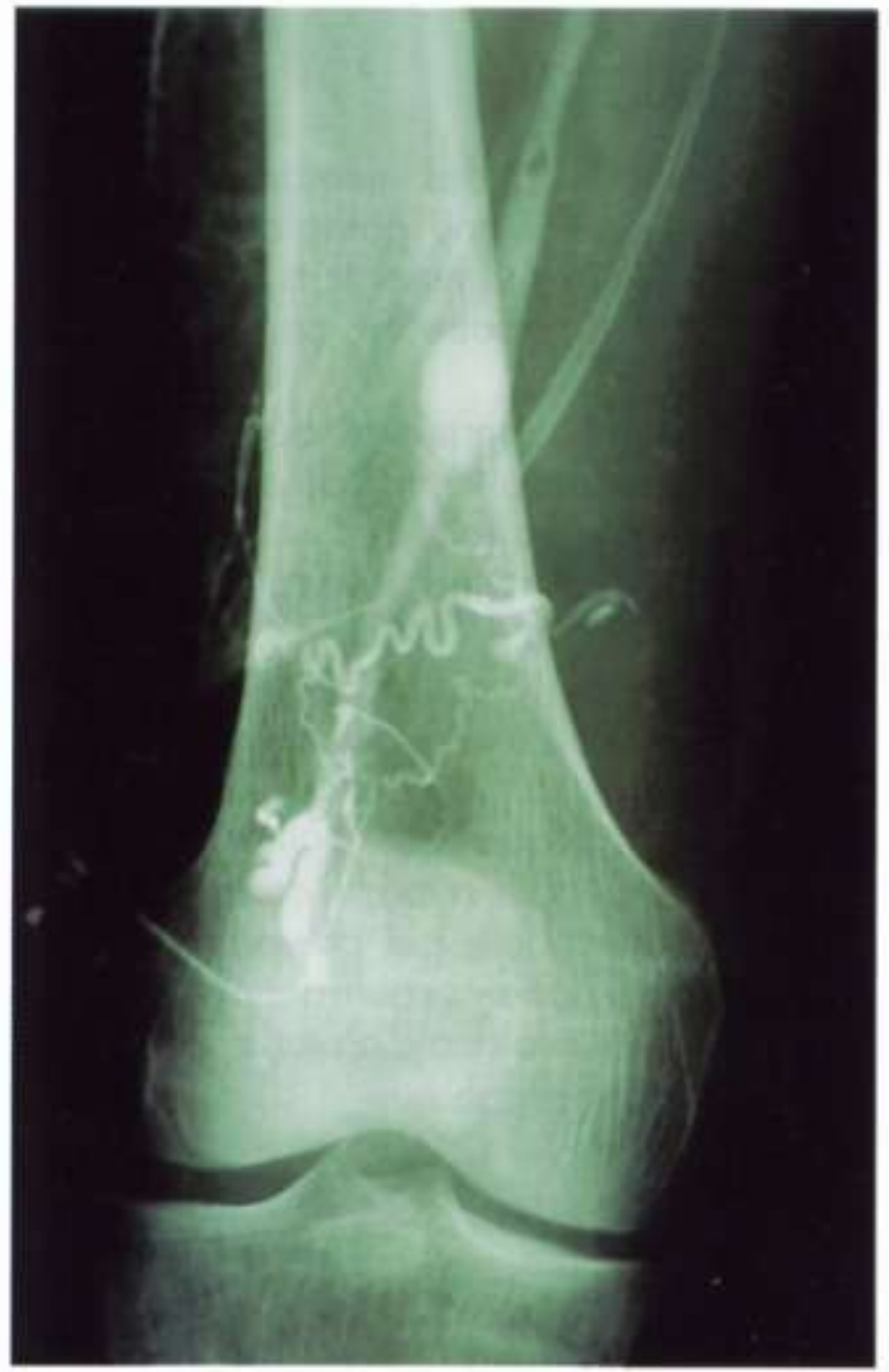
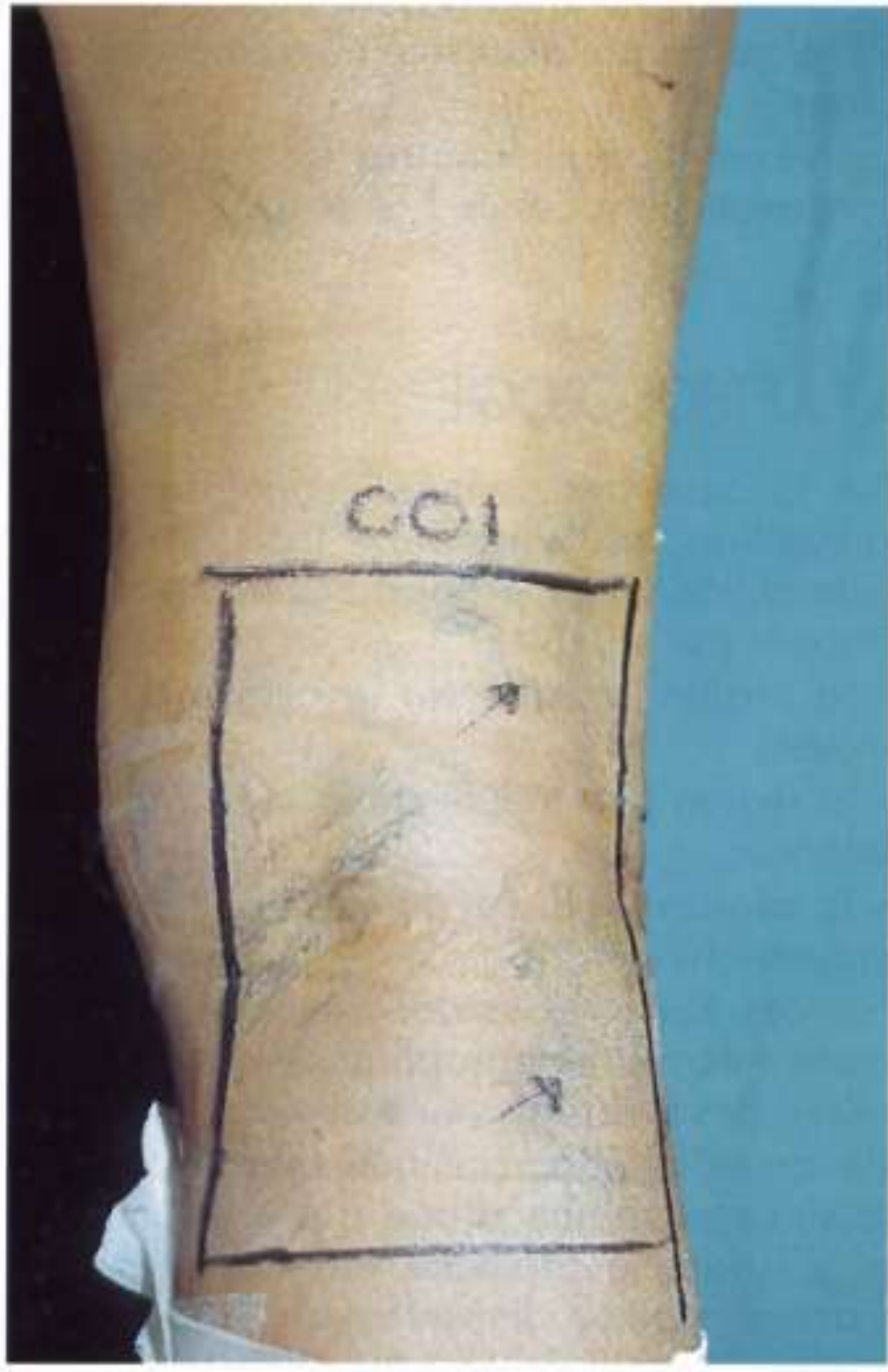
III Type

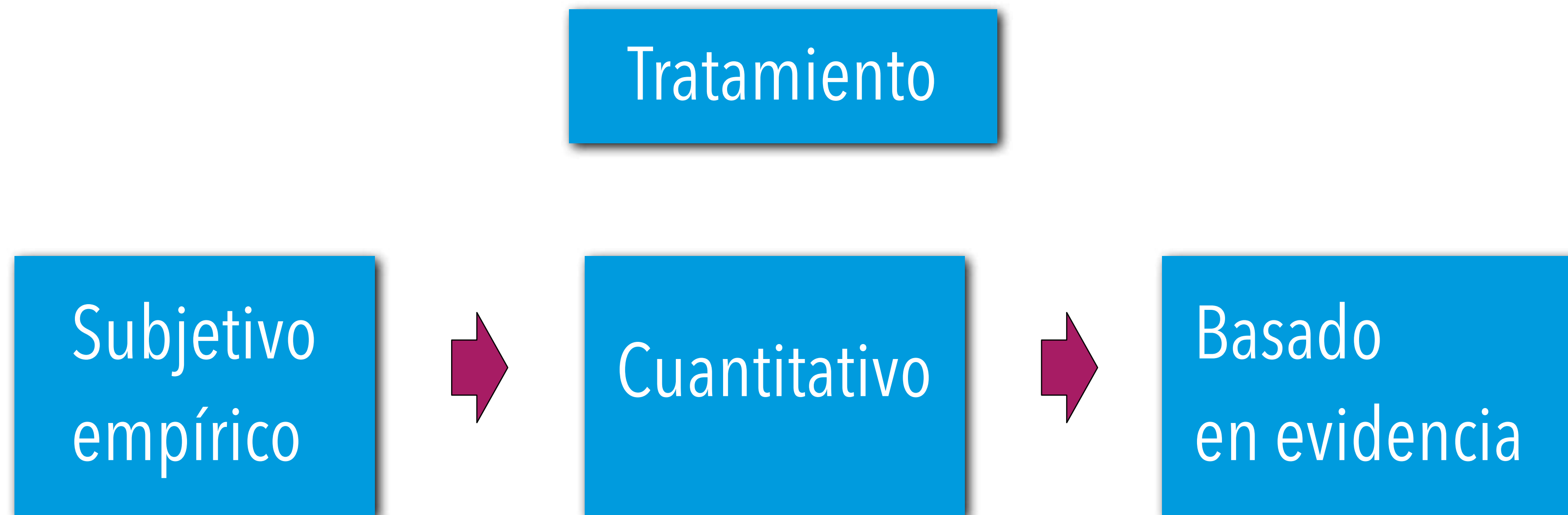




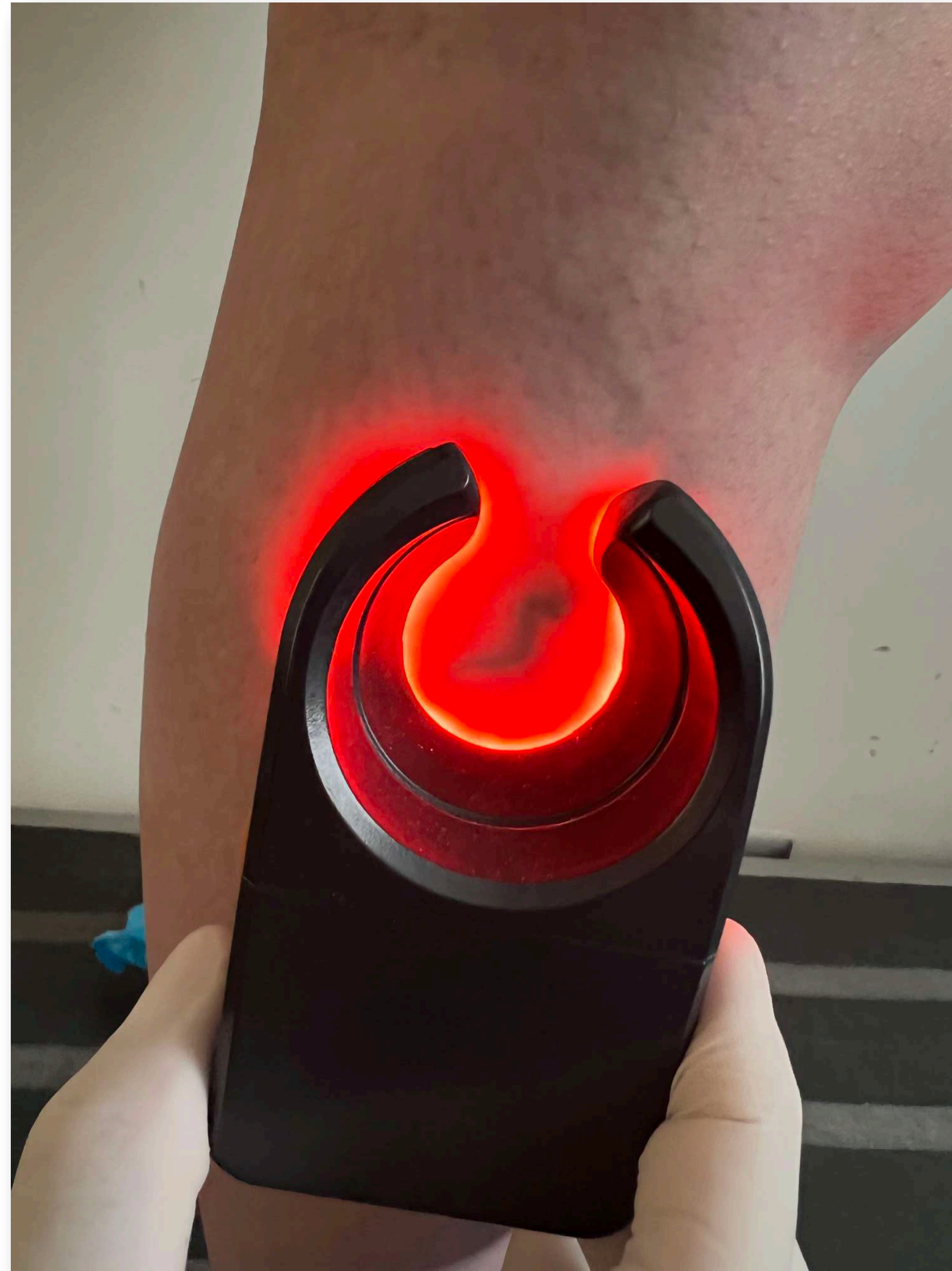


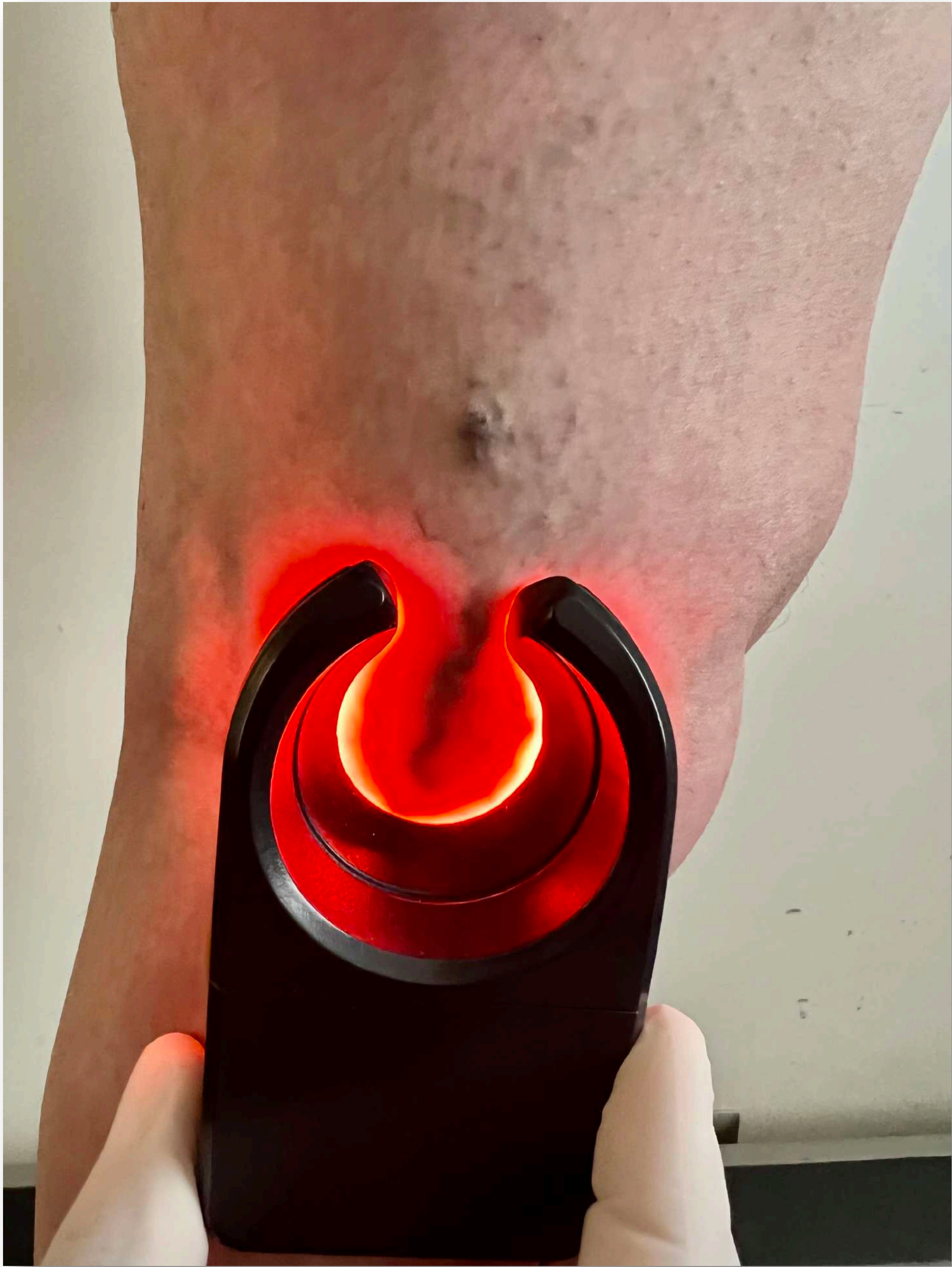

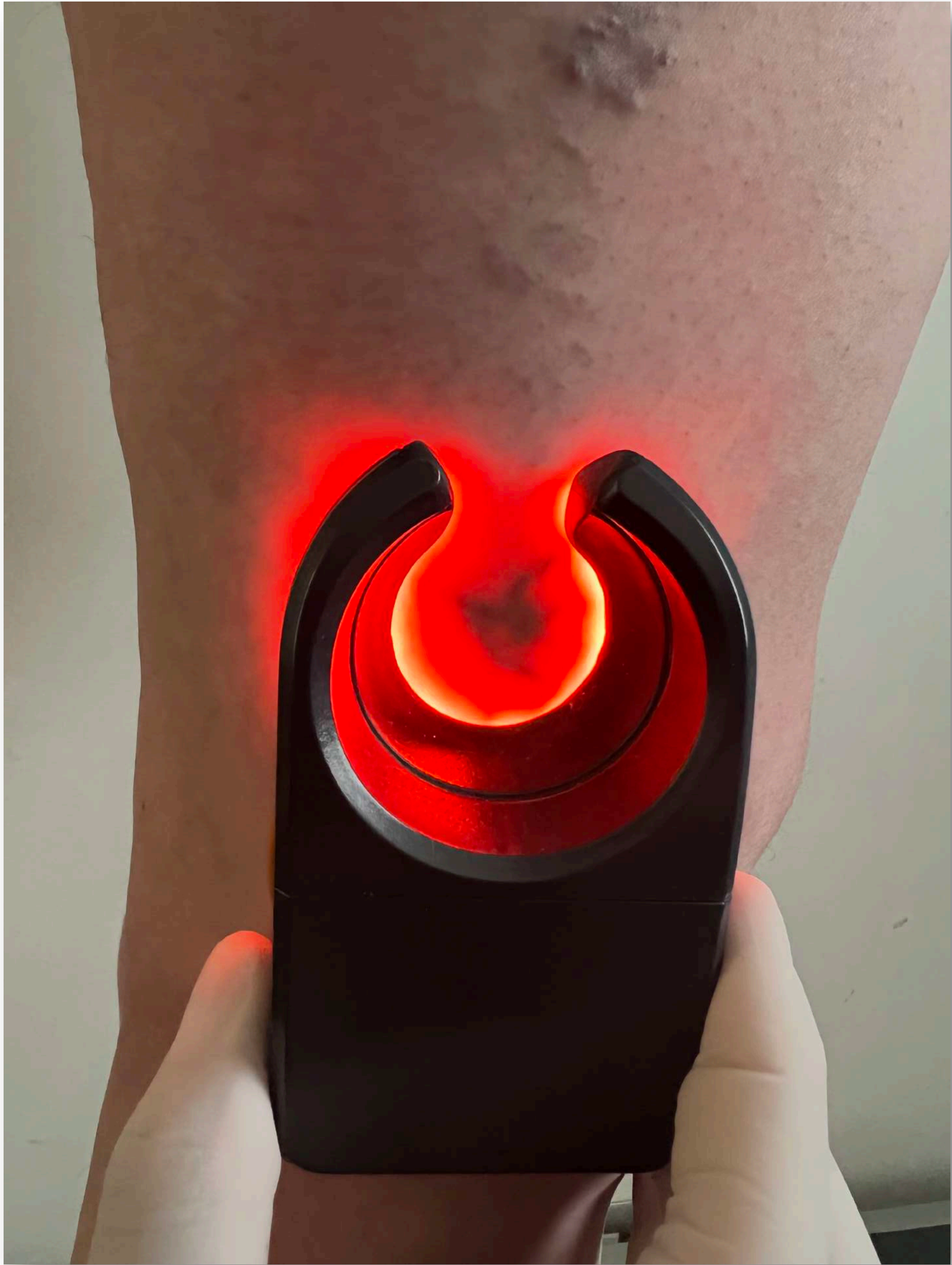Spectroshade











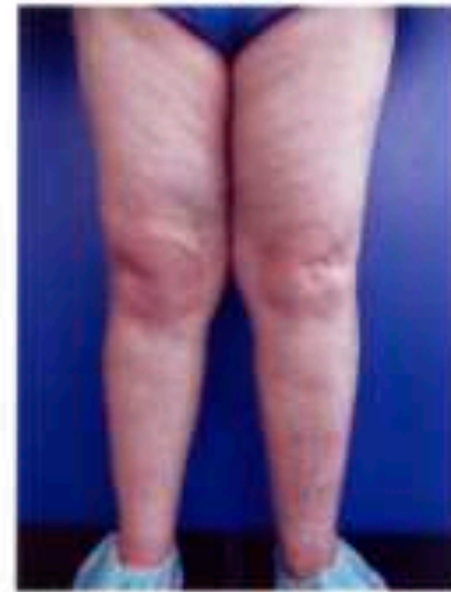Paciente:

Procedimiento: LASER + FLEBECTOMIA.

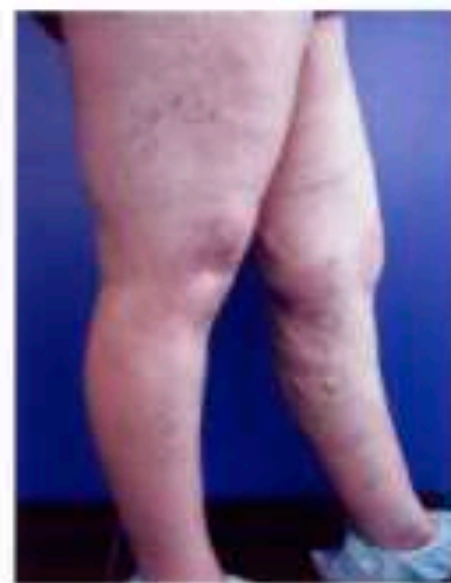
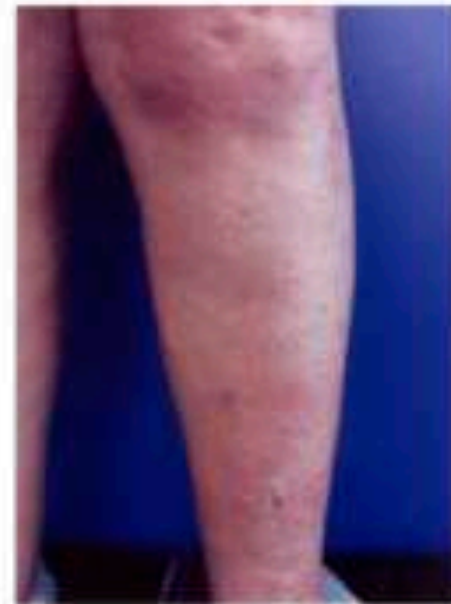Diagnostico: VV + RV + SV.

Fecha: 06.10.2003.

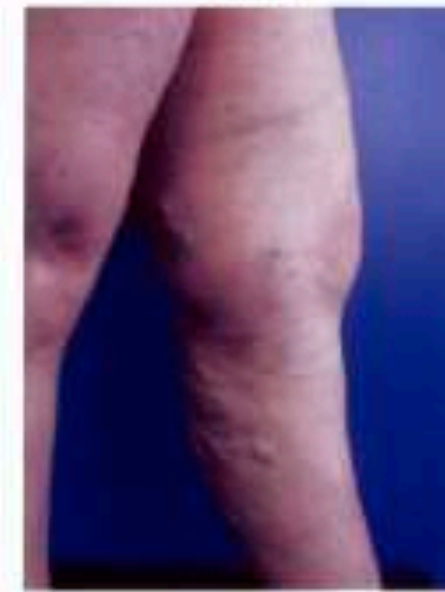Antes



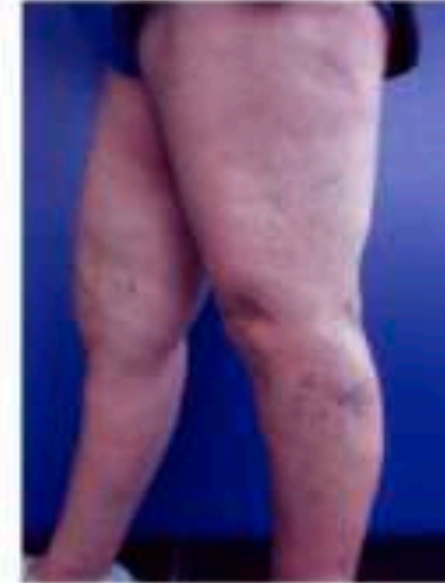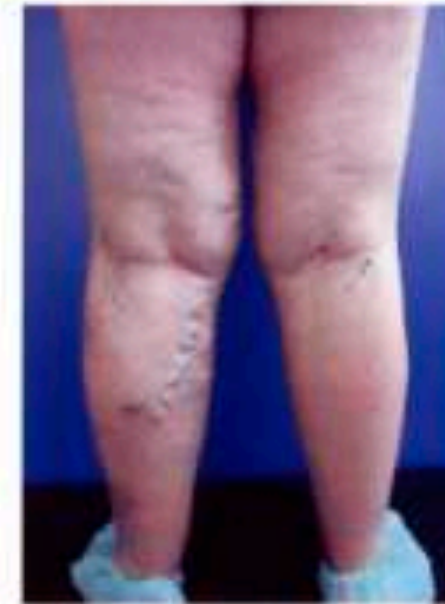Después

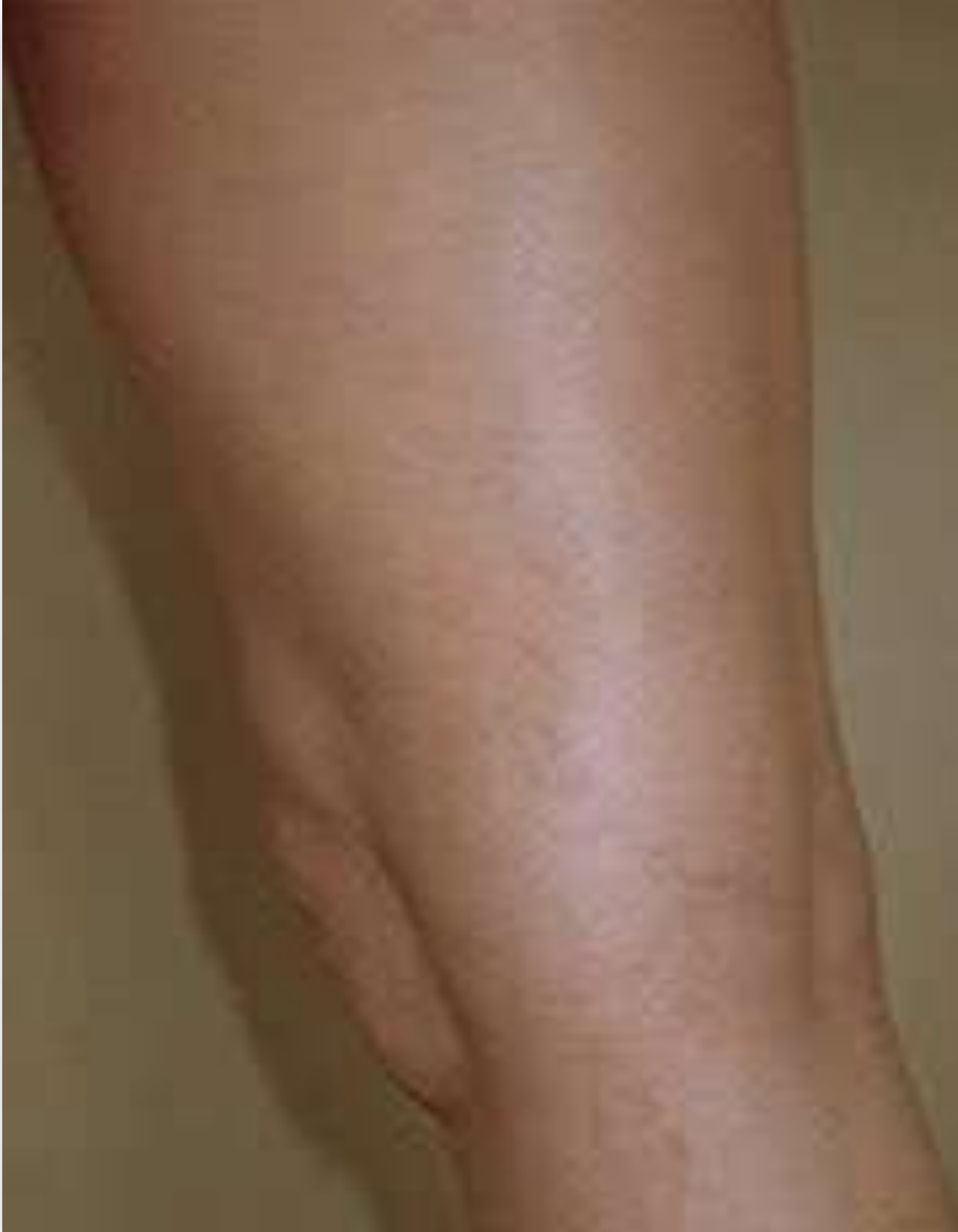
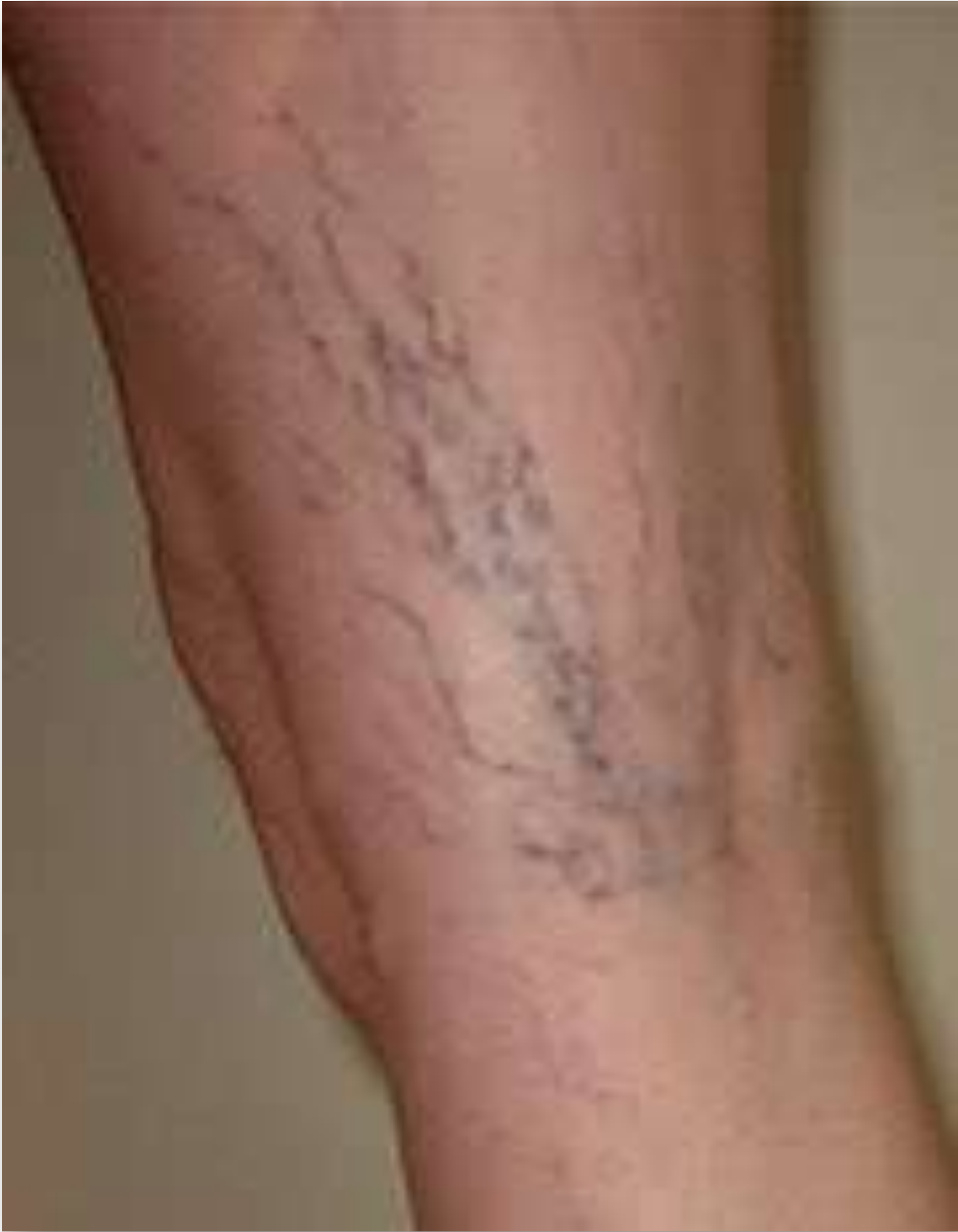
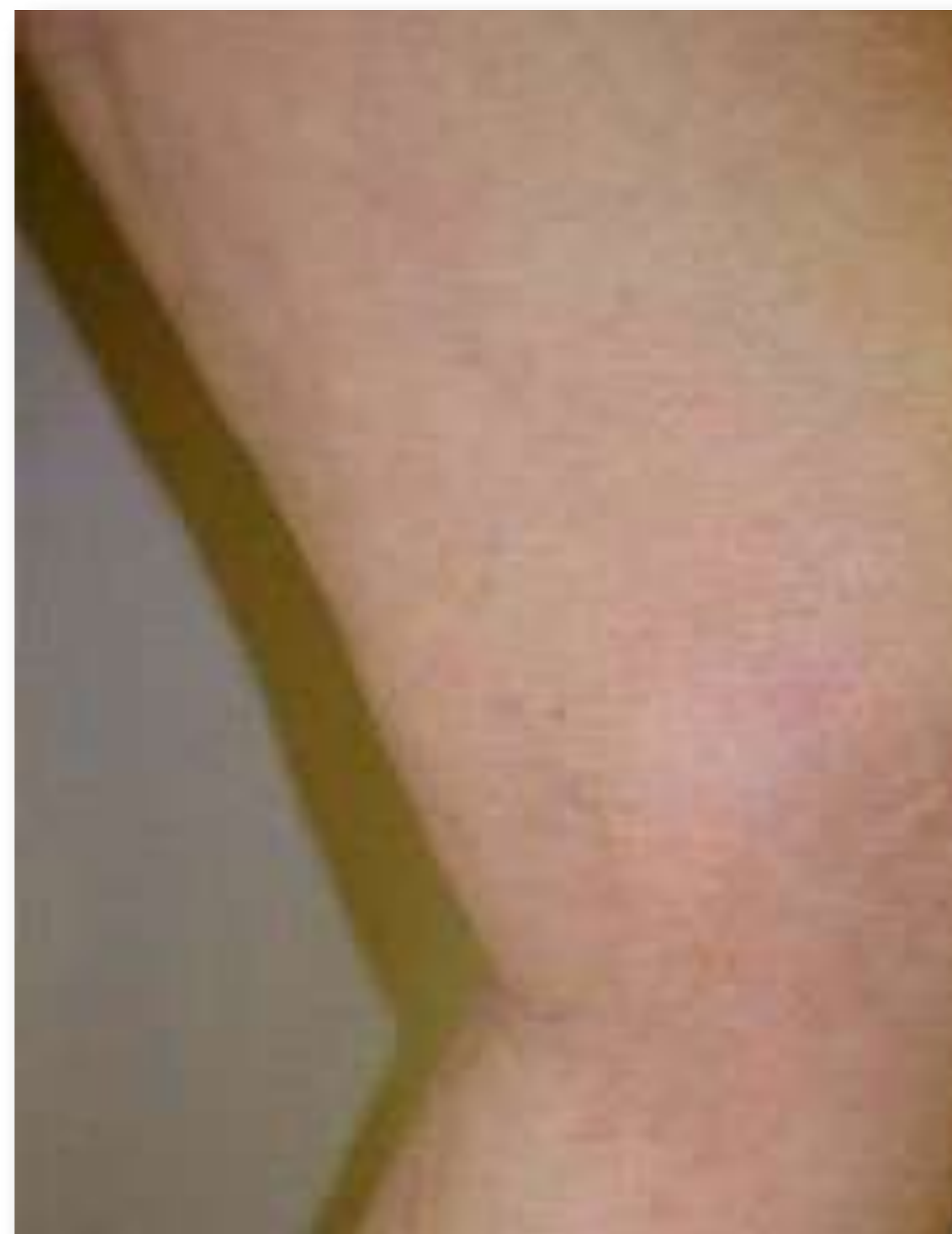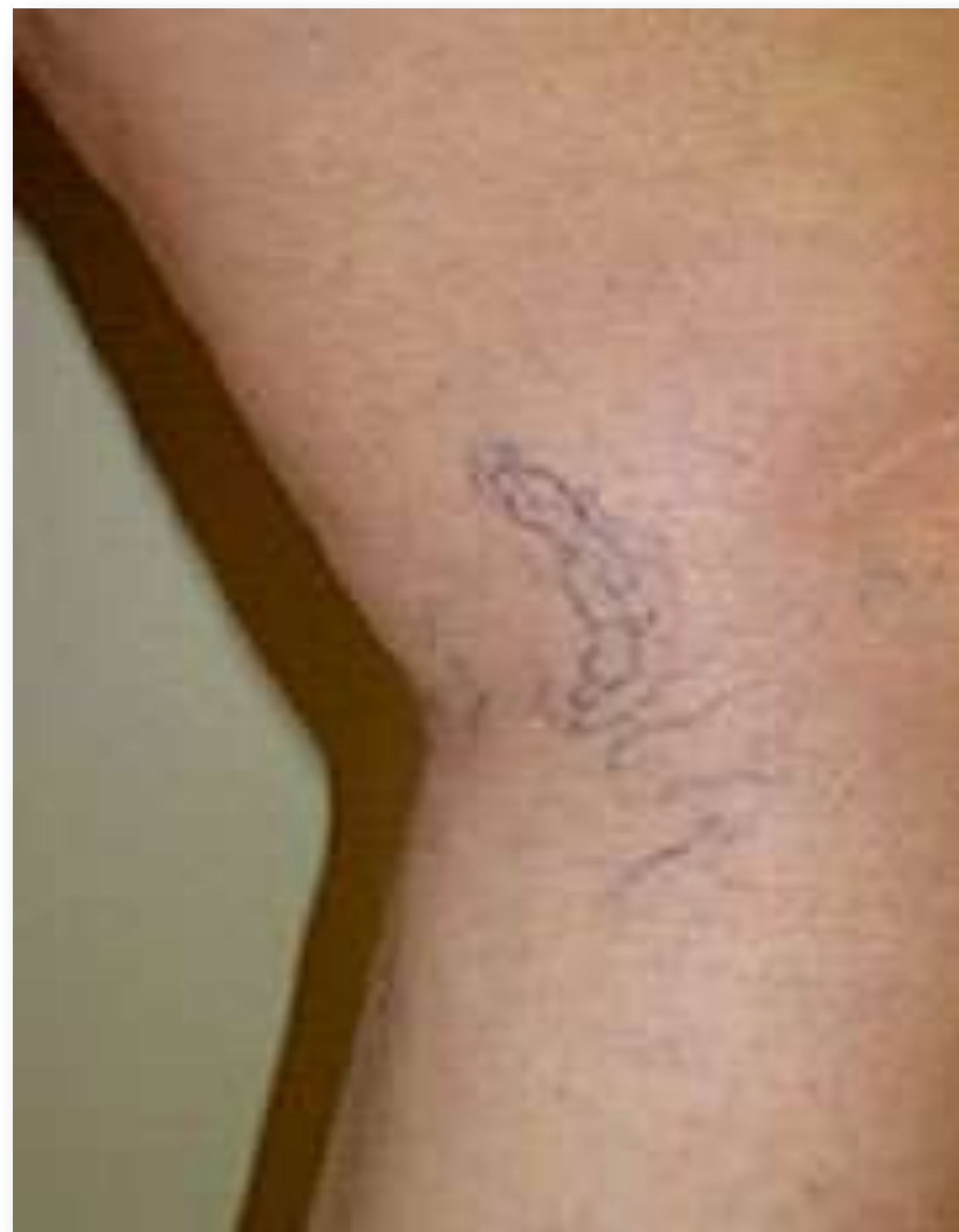Antes

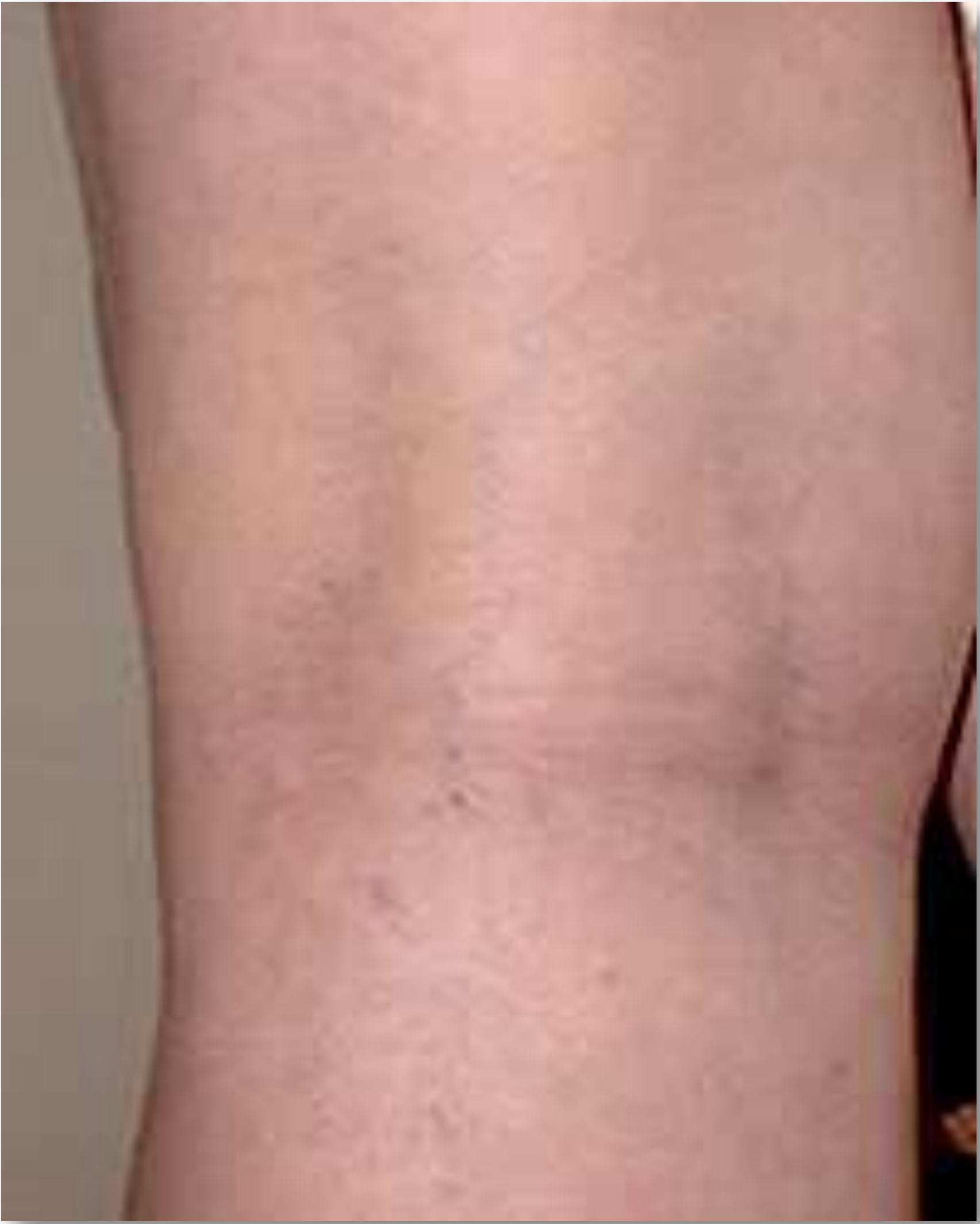
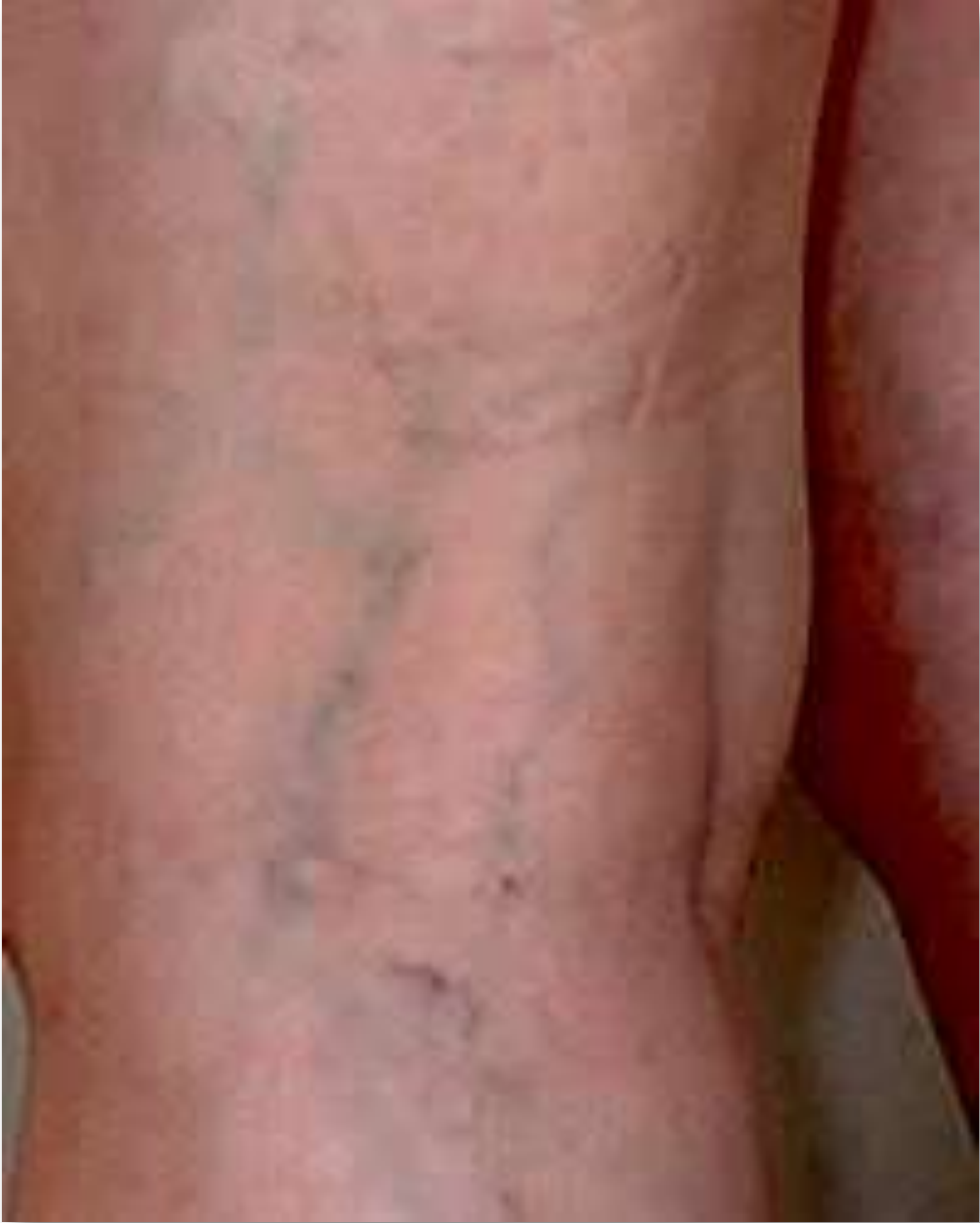
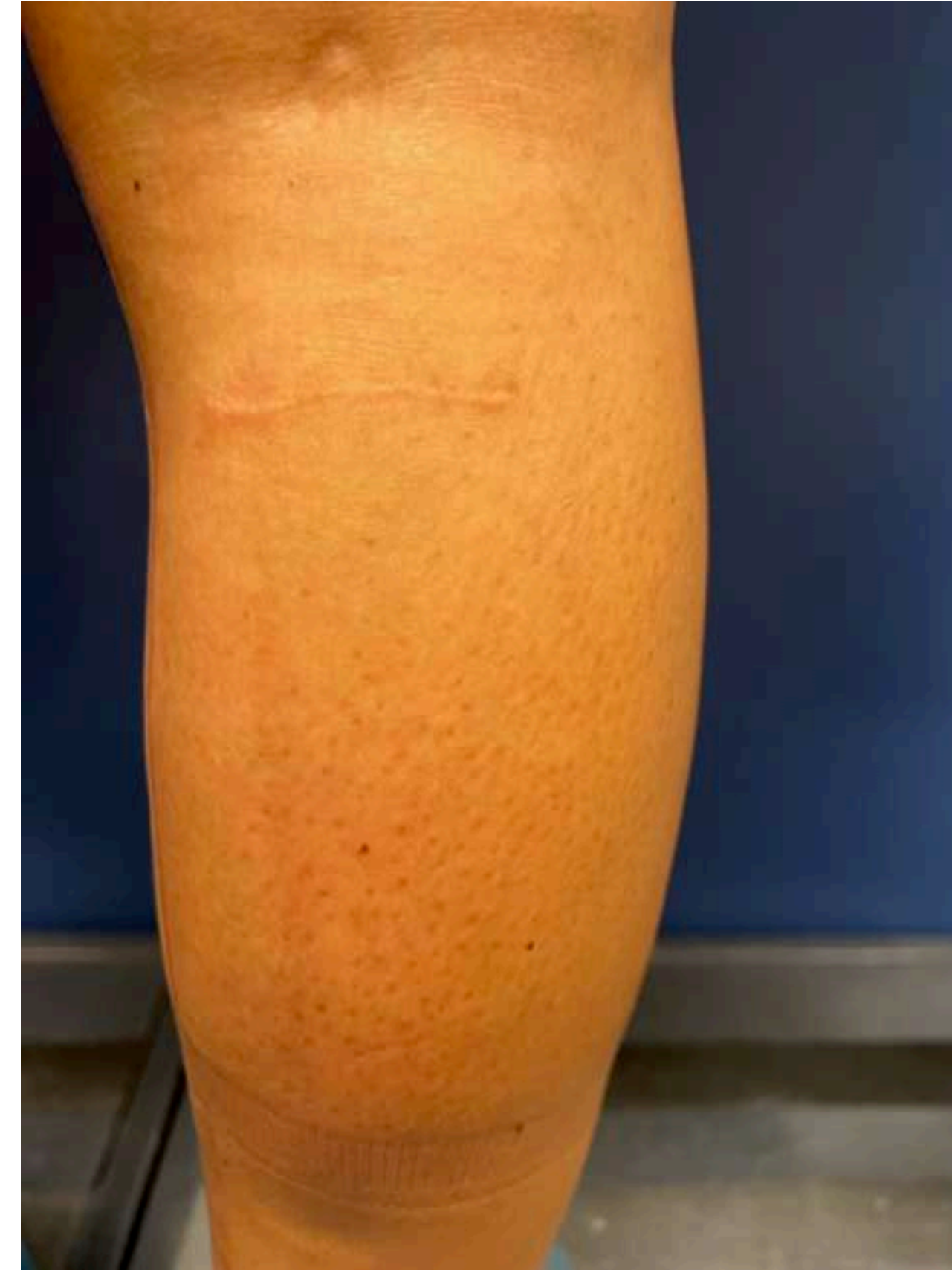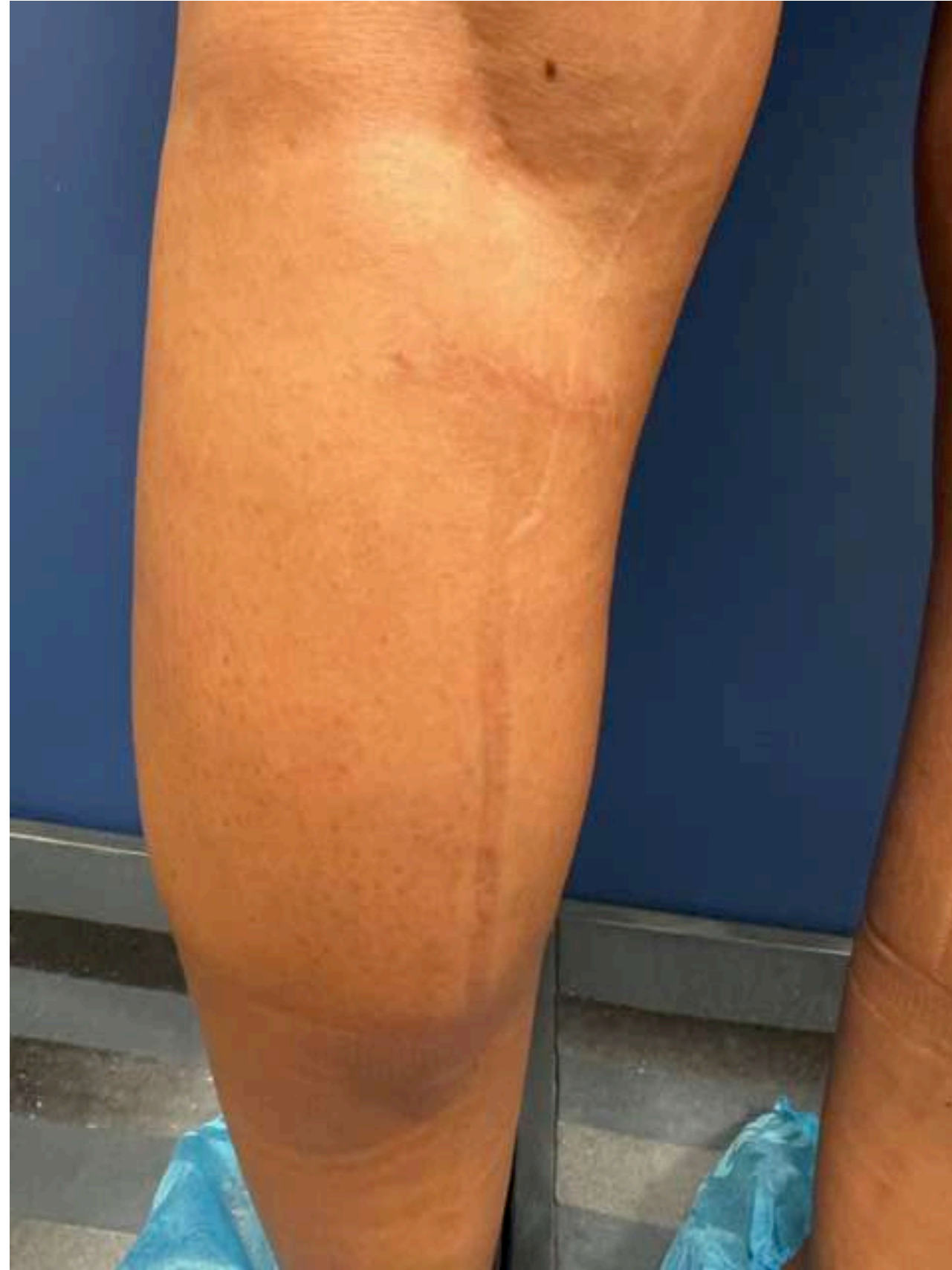Después

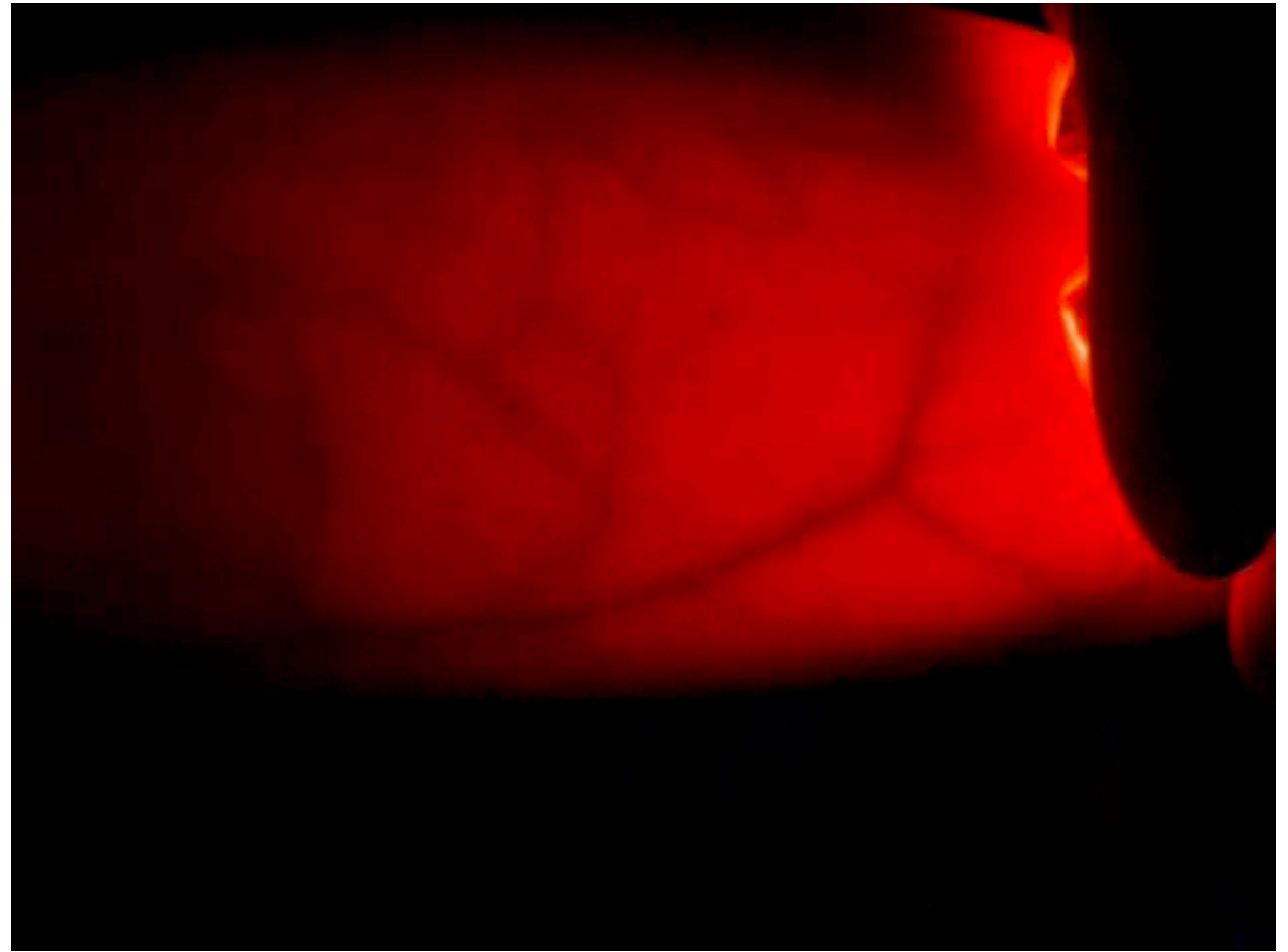
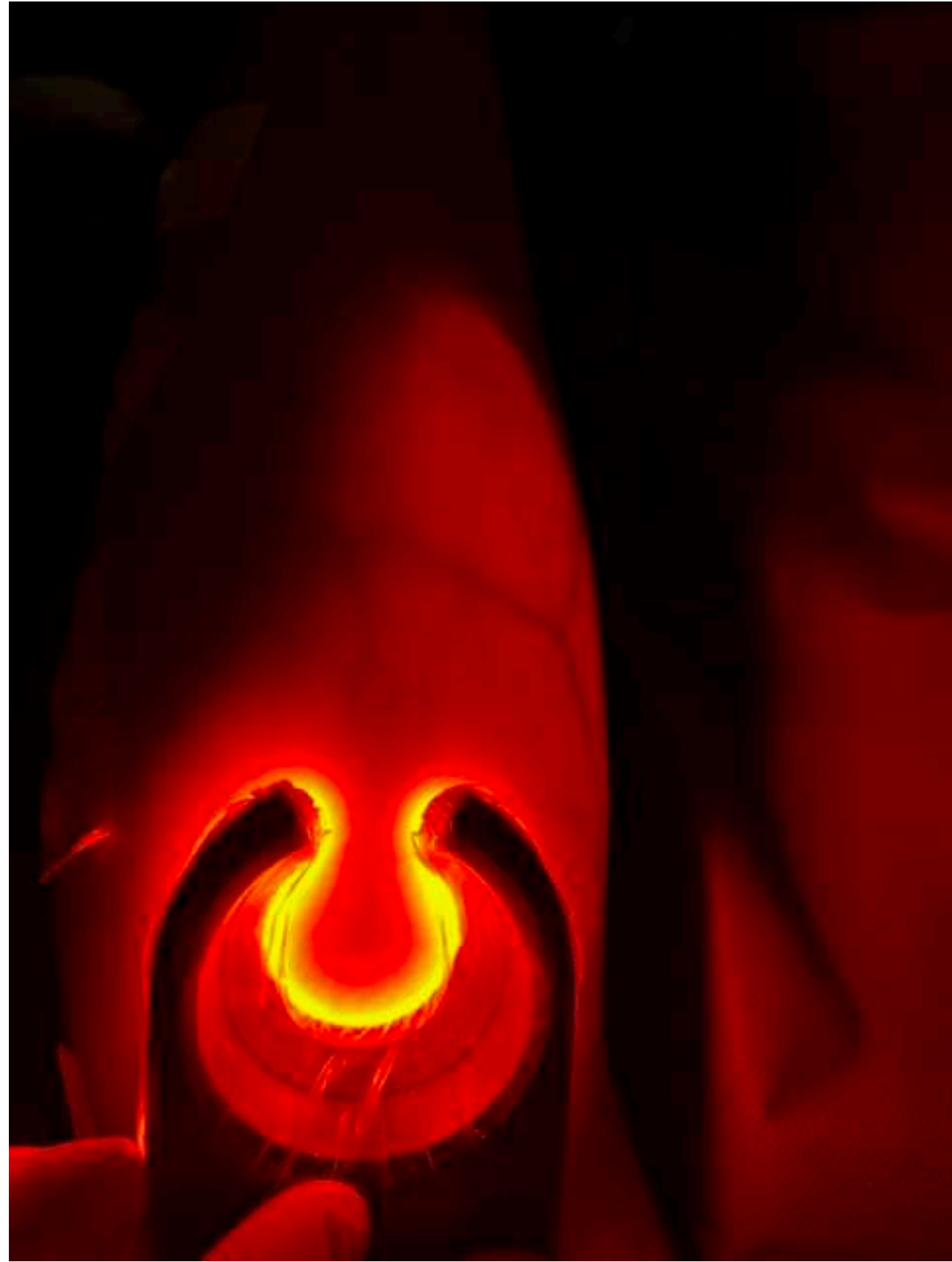


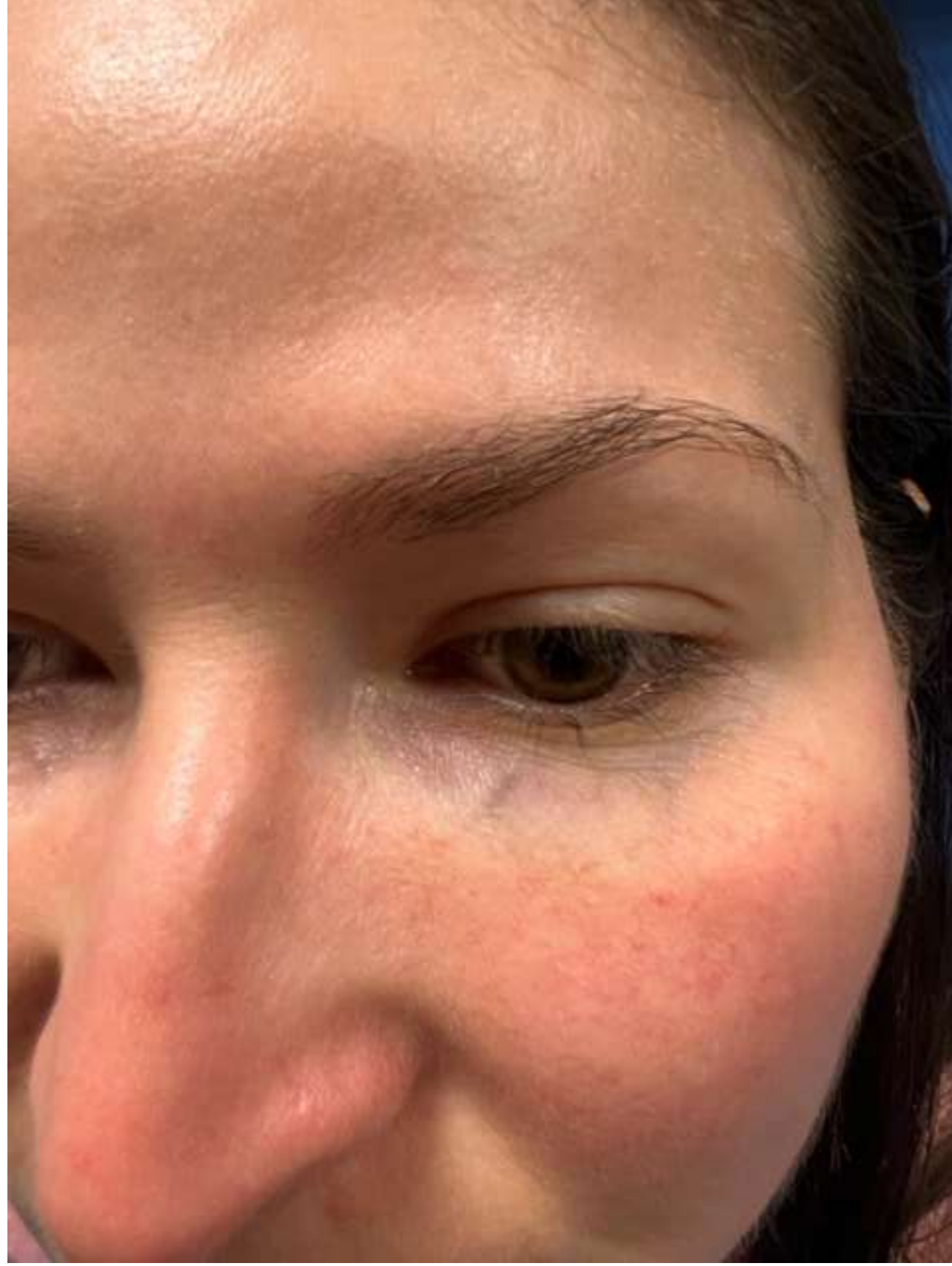
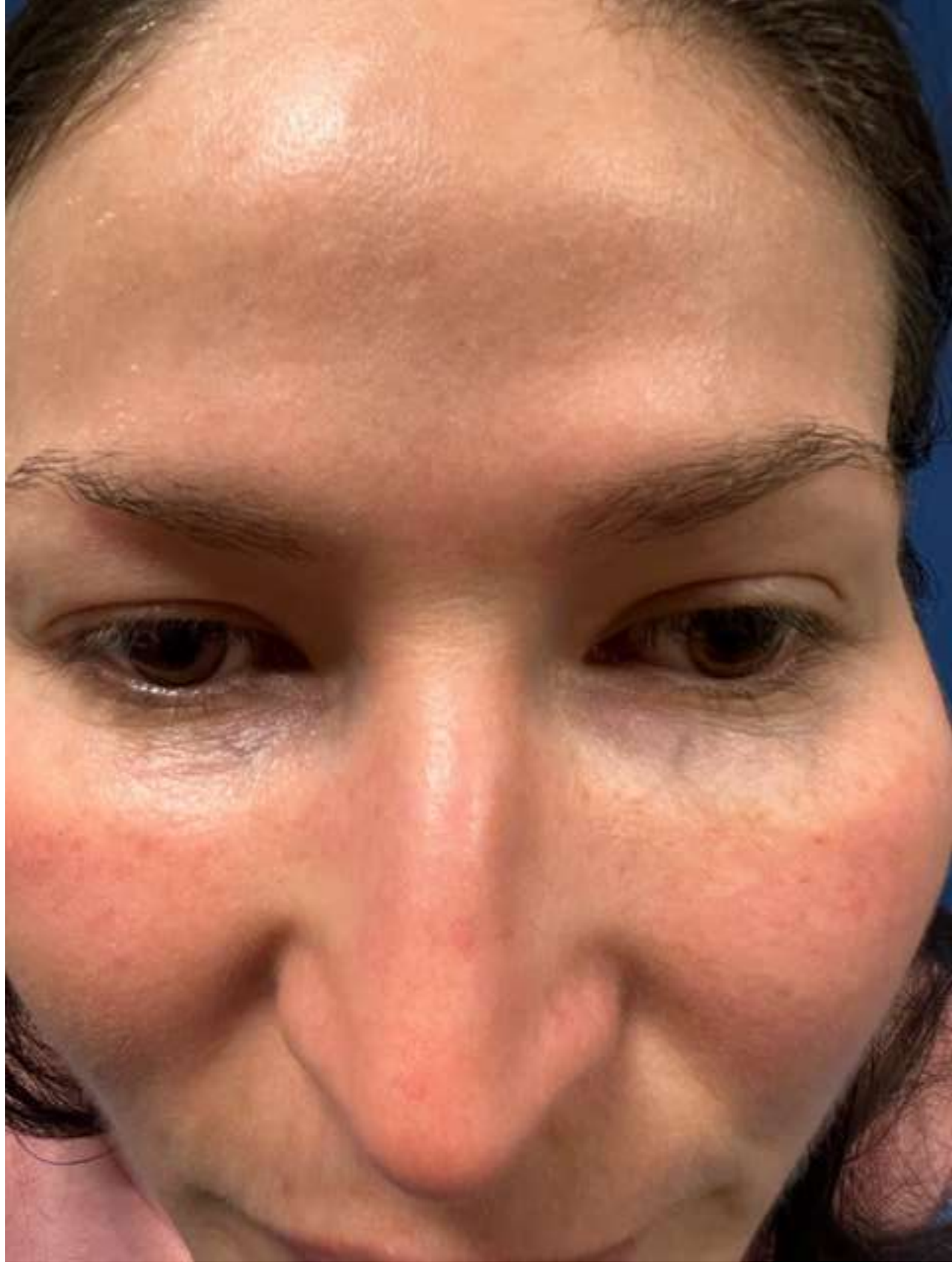










Tratamiento

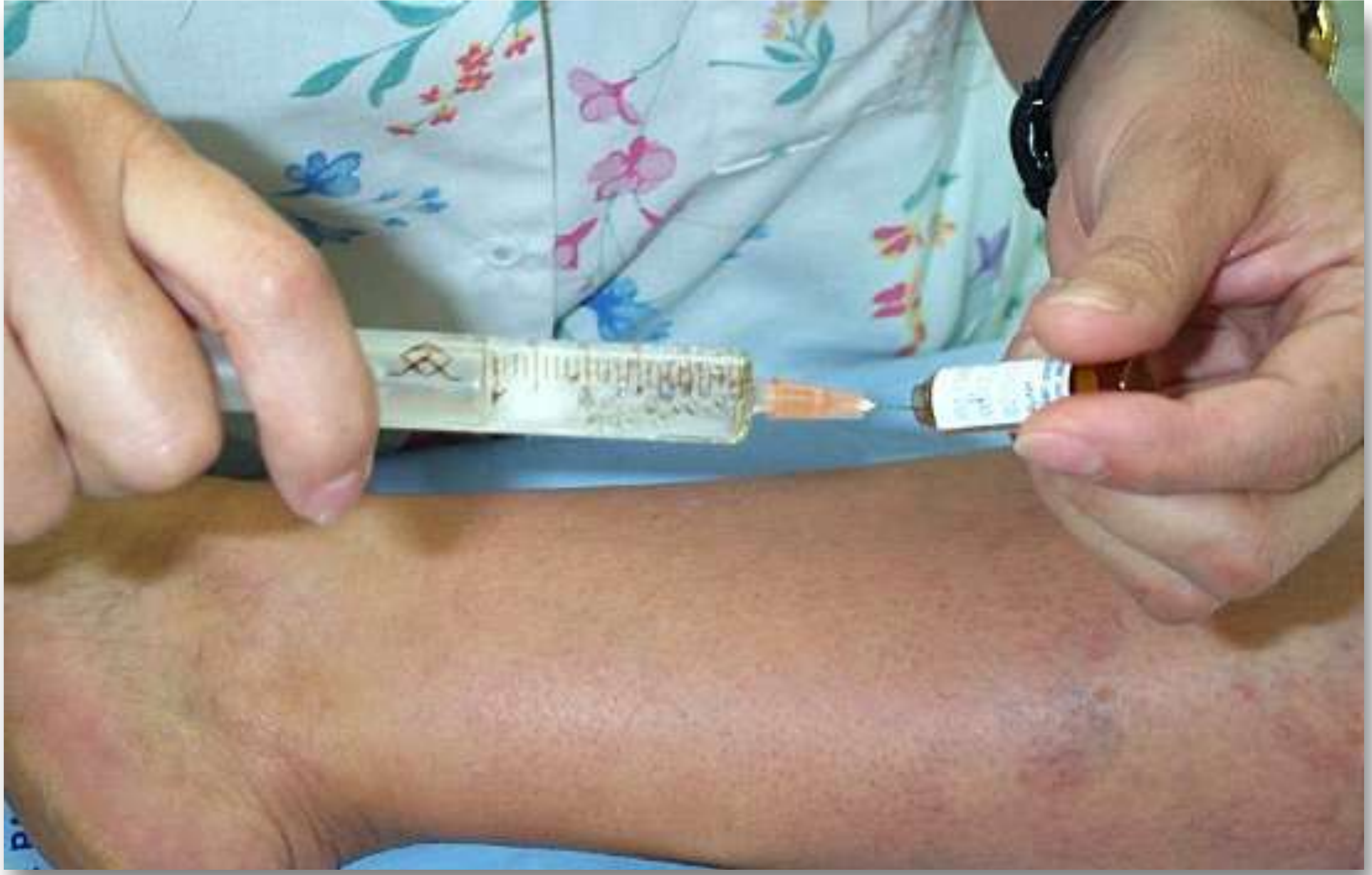Foam sclerotherapy

Zotradecol 0,2 %

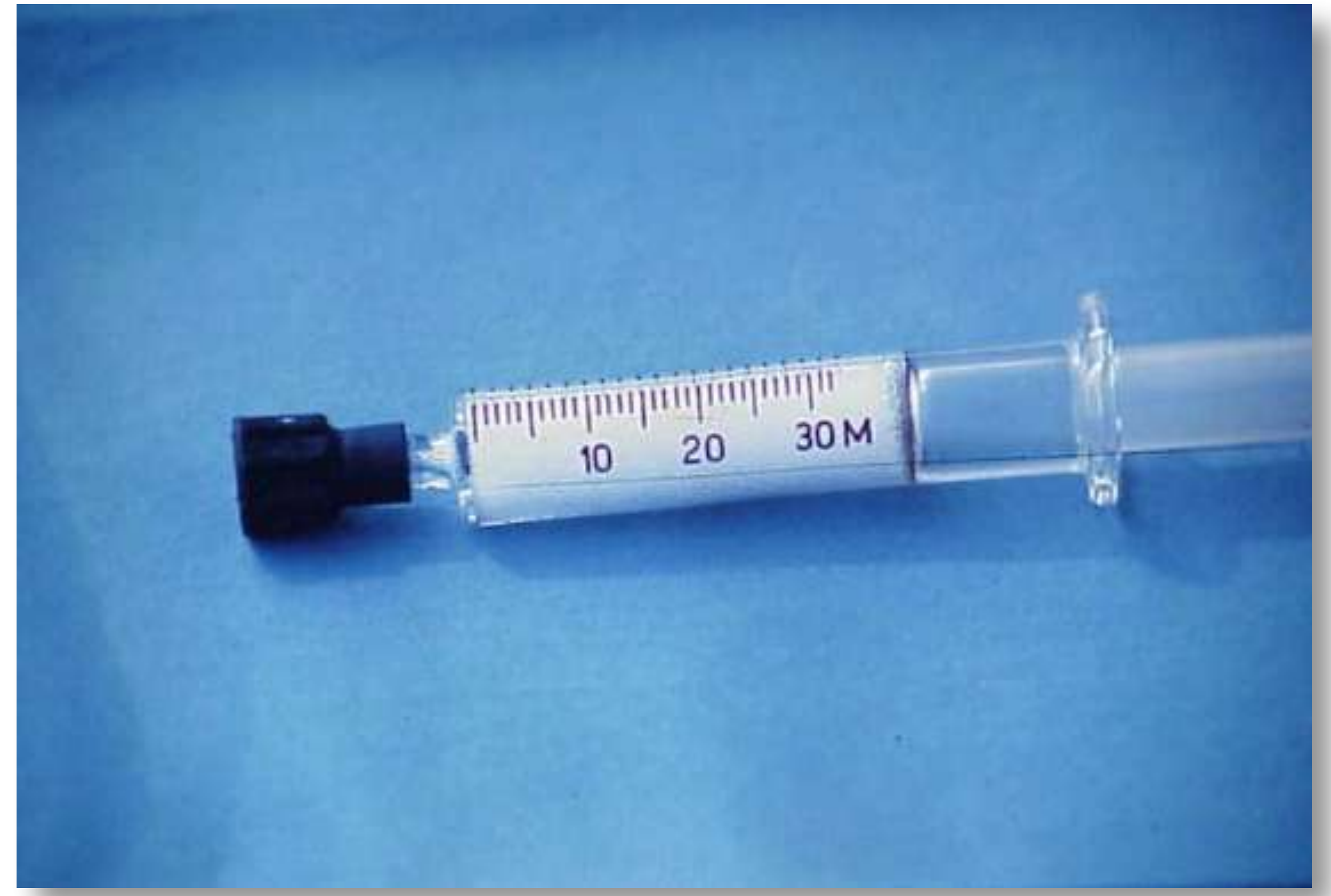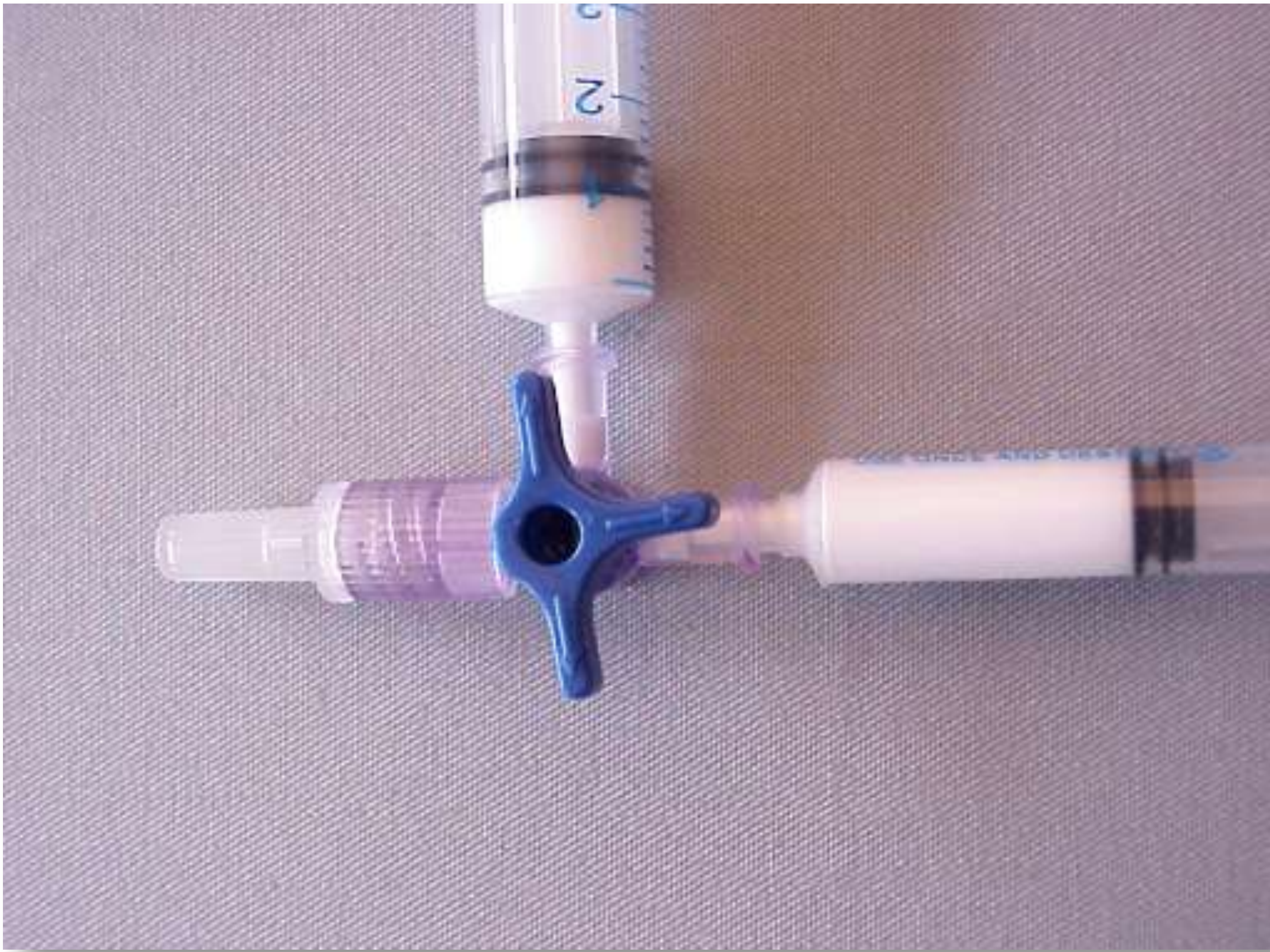
Polidocanol 0,5 %

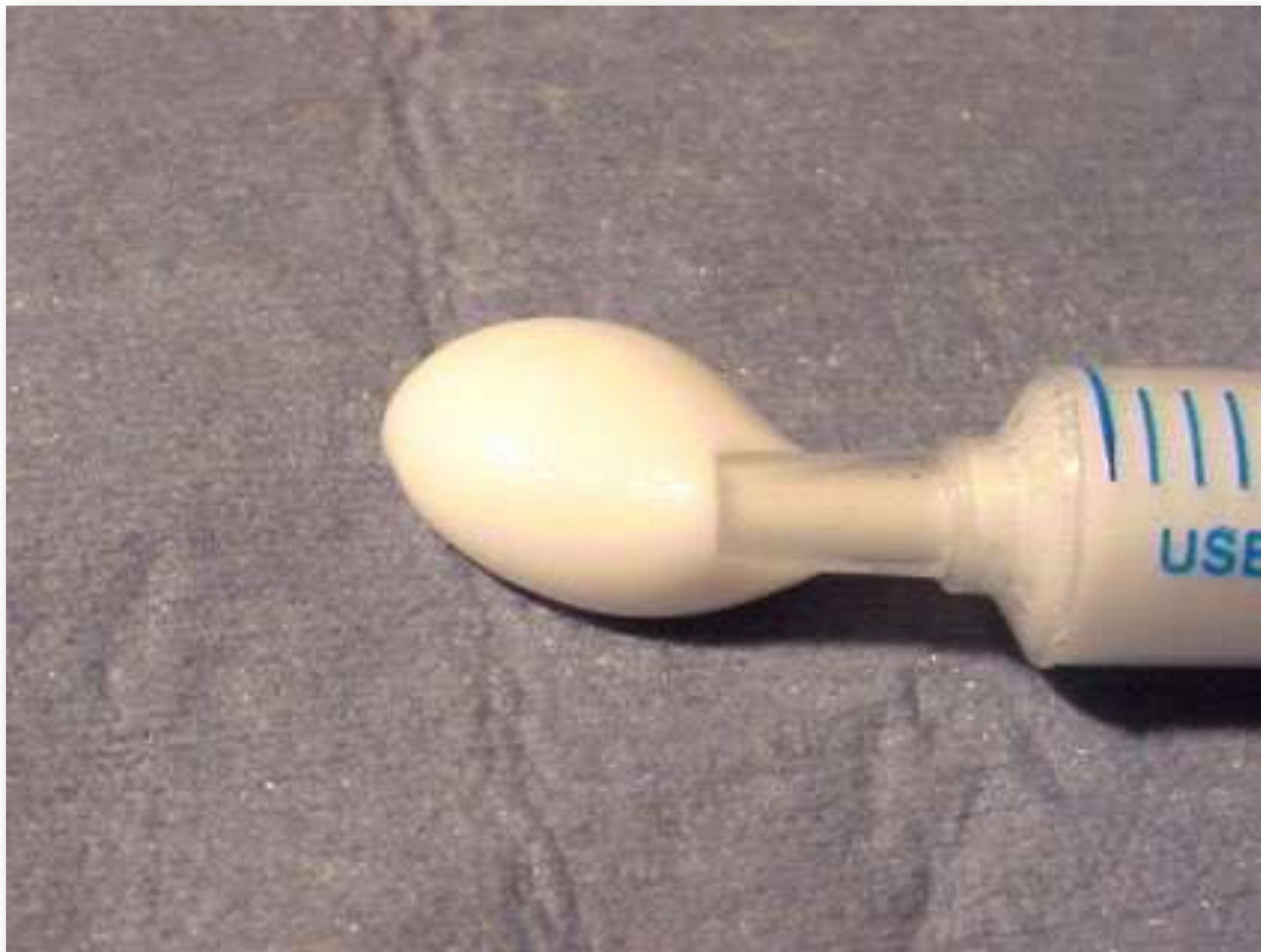Soporte elástico (20-30 mmhg) 3 semanas

Varices reticulares



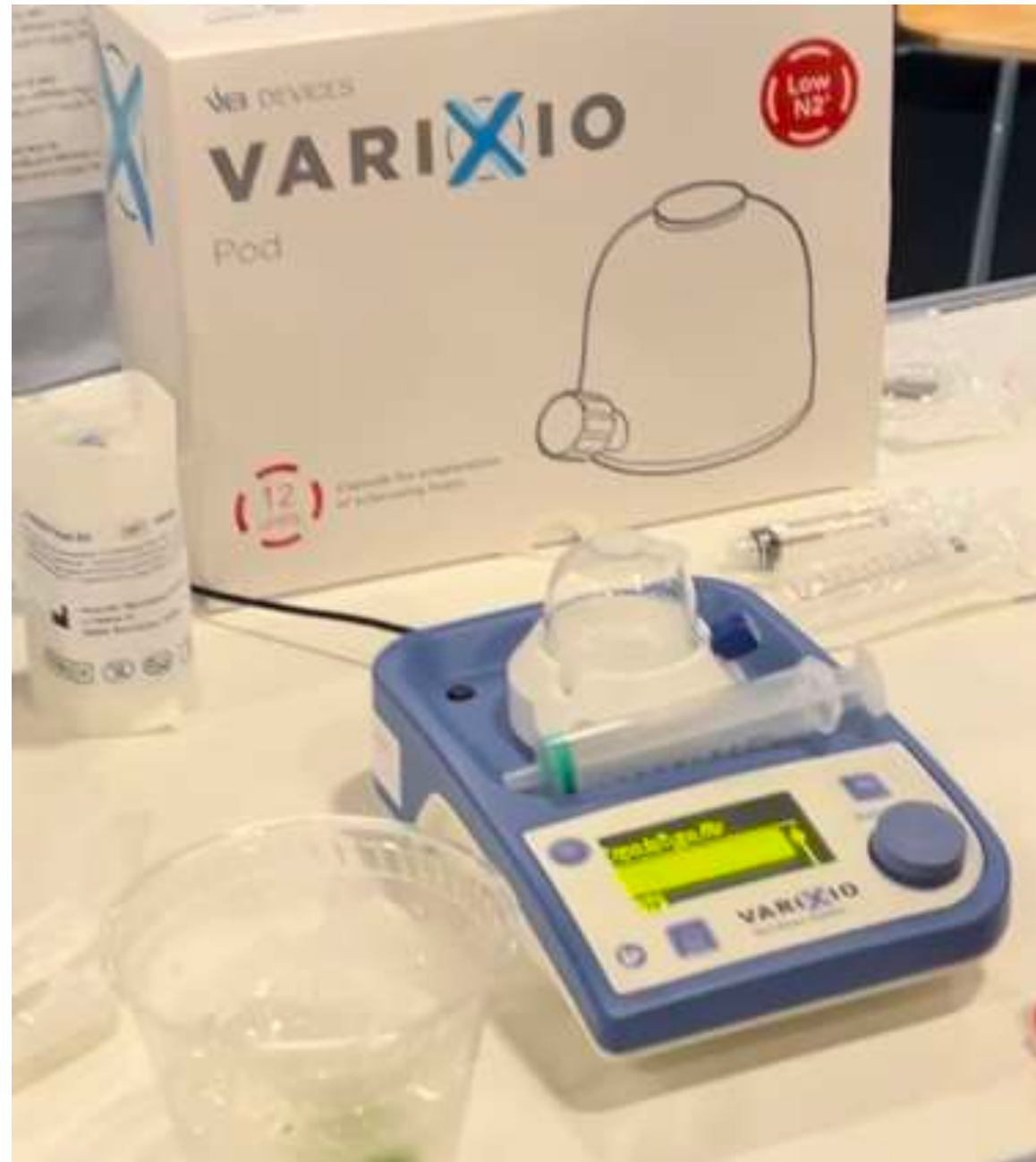
Fotos foam
















Tratamiento

SPIDER VEINS (< 1mm)

Micro-Sclerotherapy

Polidocanol 0.5%

RETICULAR VEINS (1 - 3 mm)

Polidocanol 1.0 %

Tratamiento

SECUENCIA POR ETAPAS

Varices

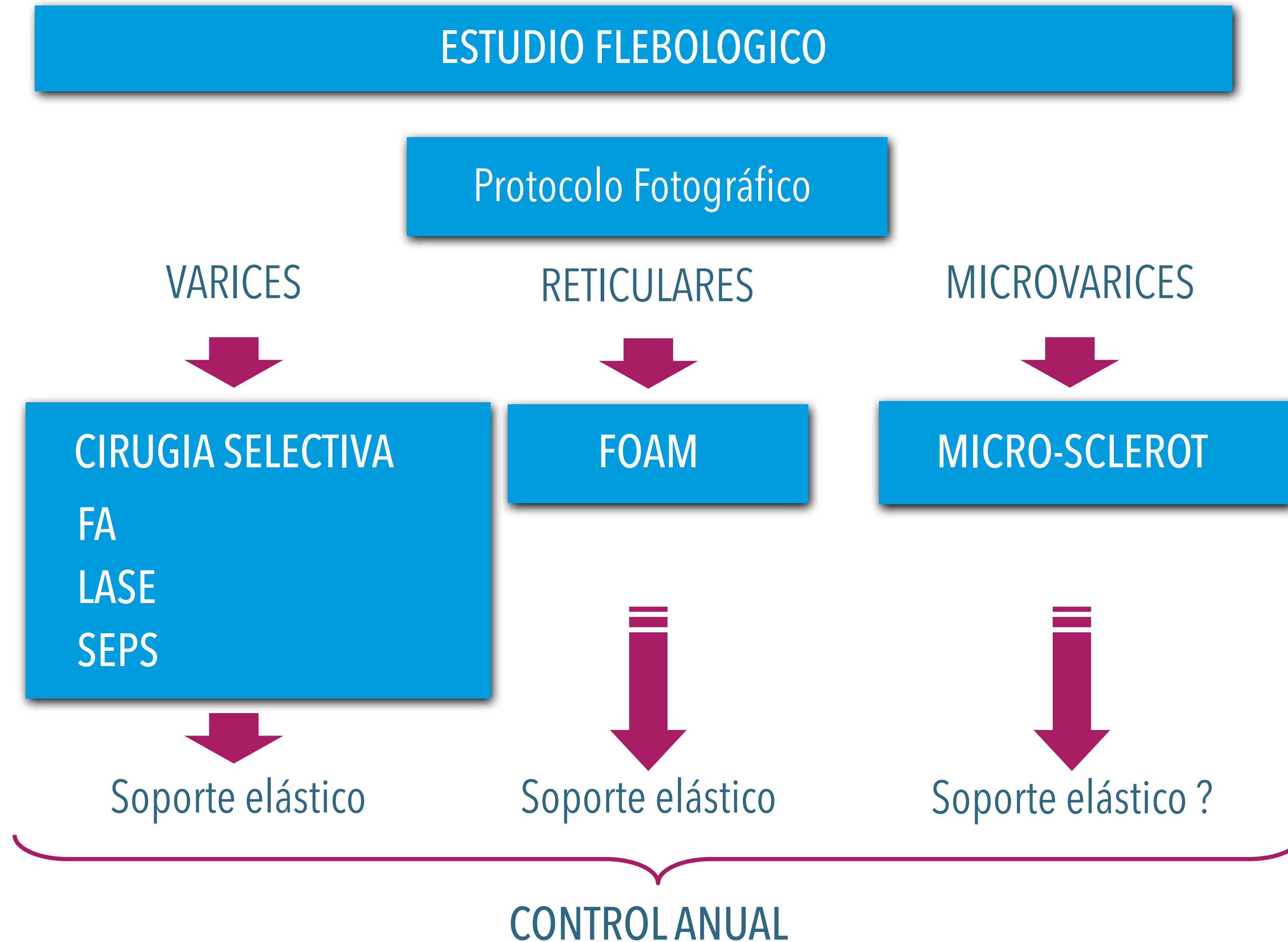
(Falla valvular)

LASE
FA
SEPS

Reticulares

Telangiectasias

Nuestro día a día



COMPLICACIONES

Matting

Pigmentación

Angiogénesis

Alergia

Broncoconstricción

ANALGESIA ??

MEDICAMENTOS

FRIO

PARCHES (versstis)

PROPIOCEPCION

Refractariedad

< 0,2 mm
muslo
severidad
reflujo (30 %)

Duffy, University of Southern California

Weiss, John Hopkins U. School of Medicine, Baltimore.US.

Coadyuvantes

¿Soporte elástico?

¿Medicamentos?

¿Hormonas?

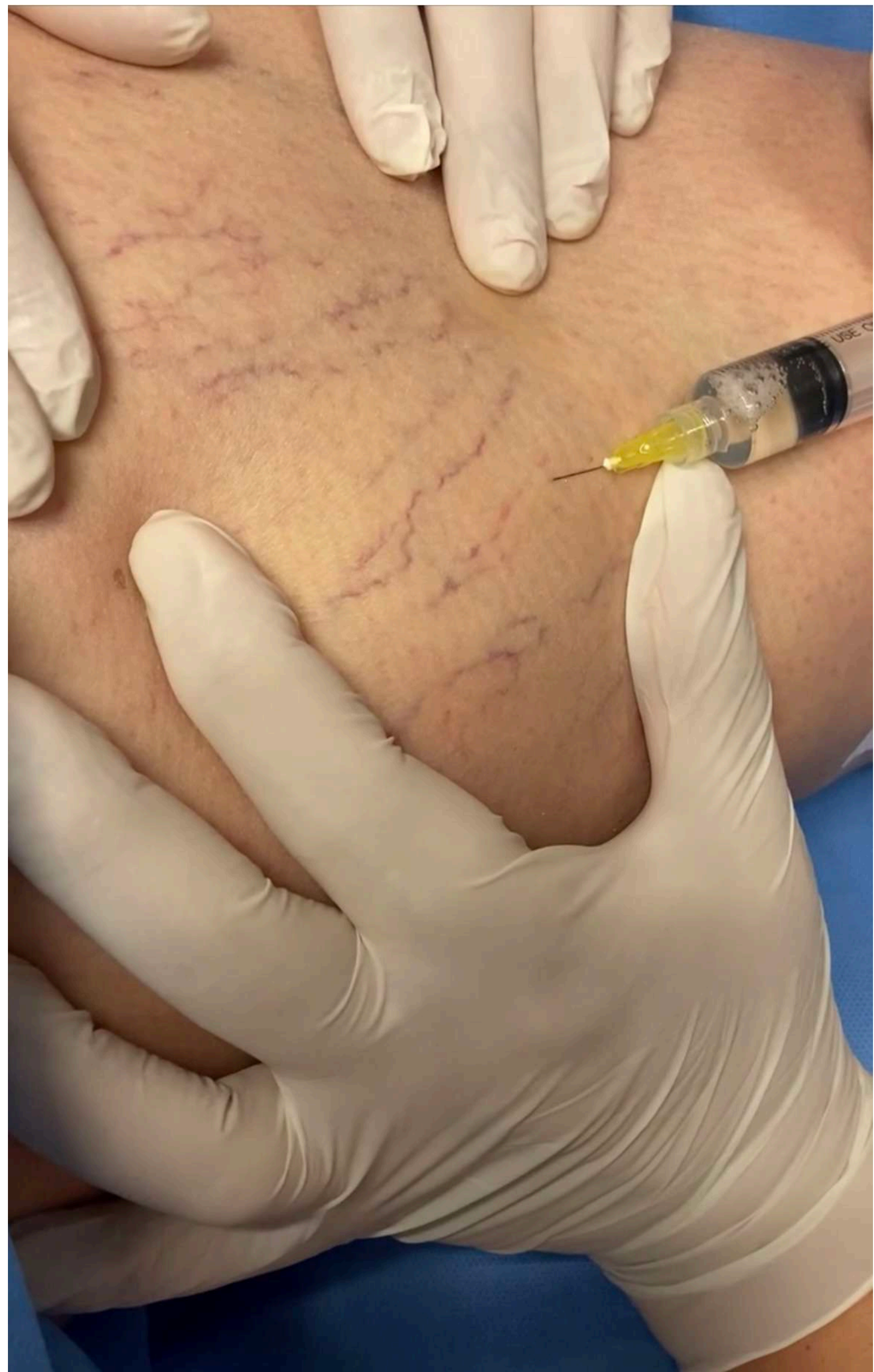ESCLERO

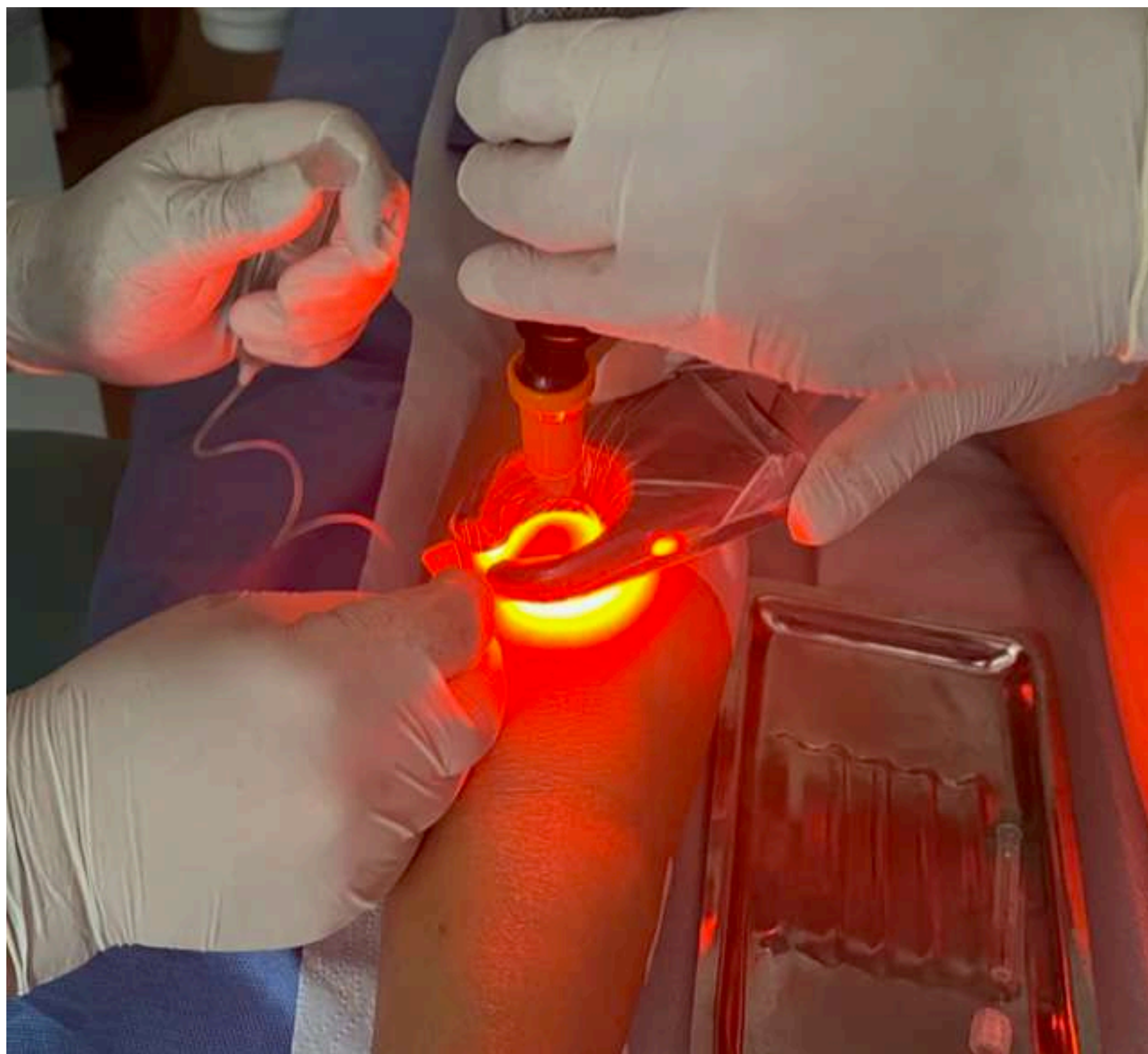BASICA

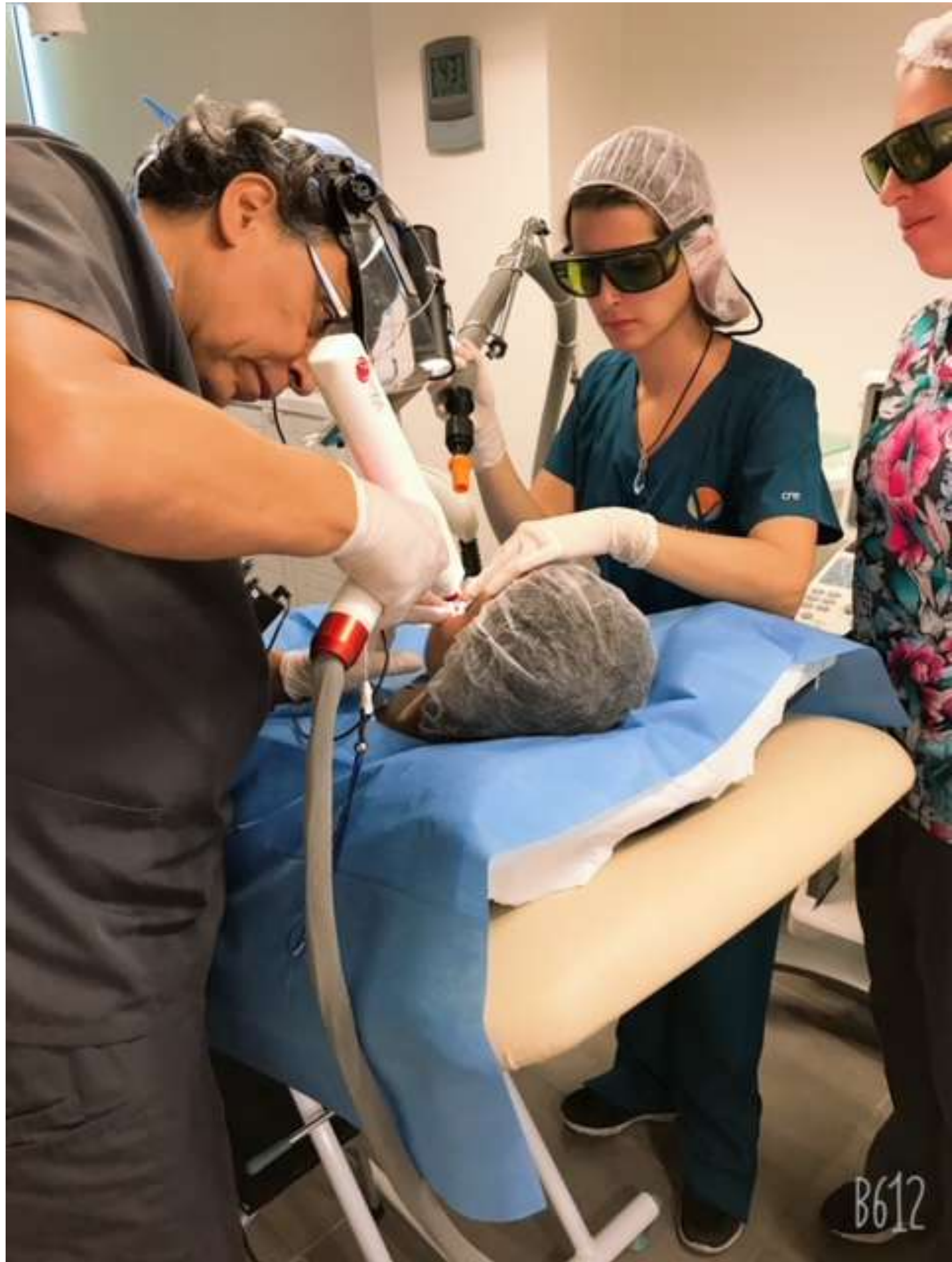INTERMEDIA

AVANZADA - PREMIUM

IVT INSTITUTE
OF VEIN TECHNOLOGY











VARICES RETICULARES MICROVARICES TELANGIECTASIAS

Dr. Alejandro Cabrera M.